

# Finite Element Modeling of Complete Unilateral Cleft and Palate using MIMICS

(Maxillary dimensional changes in a Finite element model of a human complete unilateral cleft lip and palate)

Balakumaran. V<sup>\*</sup>, Pandurangan Harikrishnan<sup>\*\*</sup>, D. Ashok Kumar<sup>\*\*\*</sup> and V. Magesh<sup>\*\*\*\*</sup>

**Abstract:** Cleft lip and palate is one of the commonest congenital craniofacial defects which primarily affect the facial bones. The unilateral cleft lip is a condition where there is a gap in the upper lip on one side that extends to the nose. Cleft palate is the condition where the two plates of the maxilla (upper jaw) are not united in the midline, leaving a gap. In a complete unilateral cleft there is an opening on one side that extends to the alveolus and into the palate. The objective of this work is to create a finite element (FE) model of the human skull with complete unilateral cleft lip, alveolus and palate anomaly for clinical simulation studies. The computed tomography (CT) images was used to construct the three dimensional (3D) FE model. The model is constructed using MIMICS and 3-matic software. The complete left-sided unilateral cleft lip and palate model of the human skull with all the feature were constructed. From the constructed model the various measurements on the maxillary arch was carried to bring out the extent of deformation in the cleft maxilla. The results revealed that the maxilla is asymmetric in transverse and antero-posterior plane.

**Index Terms:** Finite element, cleft lip and palate

## 1. INTRODUCTION

Craniofacial defects are a diverse group of deformations in the skull and facial bone. Cleft lip is a congenital disorder where there is a split in the upper lip, present on one side is called unilateral cleft lip and both sided is called bilateral cleft lip often associated with cleft palate. Cleft alveolus is defect of the bone around the teeth in front of the palate, it can be unilateral or bilateral. Cleft alveolus is sometimes small or it can be a gap extending from the floor of the nose to the teeth creating a passage between nose and mouth. Cleft palate is a condition where the roof of the mouth is not formed completely, creating a gap. Cleft palate can be incomplete as a small hole or it can be a complete where the gap extends to the entire length of the palate. Cleft palate can be unilateral or bilateral. Cleft lip and palate is the most common craniofacial deformity with incidence of 1:700 live births [1]. Cleft lip and palate is predominant in male infants and cleft palate is predominant in female infants [3]. The cause is multifactorial though genes, food, medicine during pregnancy and environmental factors are the major cause. The treatment is by a multidisciplinary team approach. The development of the FE model will help to study certain clinical situations in the structural changes of such defects in the human skull.

The surgical procedures for the restoration of the skeletal defect are well established [2]. Cleft lip correction is primarily to close the gap in the lip and deals only with the closing of the soft tissue of the lip.

\* Student, M. Tech (Biomedical), Department of Biomedical Engineering, SRM University, Kattankulathur, Tamilnadu, India 603203.  
E-mail: [gvalakumaran@gmail.com](mailto:gvalakumaran@gmail.com)

\*\* Consultant Orthodontist/Oral Surgeon, Teeth "N" Jaws Center, Chennai. Prof. and Head of Orthodontics, IG Institute of Dental Sciences, Pondicherry, India. E-mail: [teethnjaws@rediffmail.com](mailto:teethnjaws@rediffmail.com)

\*\*\* Assistant Professor, Department of Biomedical Engineering, SRM University, Kattankulathur, Tamilnadu, India 603203.  
E-mail: [ashok.d@ktr.srmuniv.ac.in](mailto:ashok.d@ktr.srmuniv.ac.in)

\*\*\*\* Assistant Professor of Mechanical Engineering, SRM University, Kattankulathur, Tamilnadu, India 603203.  
E-mail: [magesh.v@ktr.srmuniv.ac.in](mailto:magesh.v@ktr.srmuniv.ac.in)

Cleft palate repair is a surgical procedure to close the gap by palatal flap mobilization. Predominantly the surgery is performed at a young age, cleft lip at the age of 3 months, cleft palate at 18 months of age and patients who have not undergone the correction surgery remain with the cleft. Cleft alveolus repair is predominantly done by inserting a bone graft to close the gap. Speech therapy and Orthodontic care is provided for appropriate treatment outcomes at specified times. The size of the maxillary arch is smaller in cleft palate patients and this smaller arch creates a misalignment between the maxilla and the mandible.

The main objective of the study is to develop an FE model of a complete unilateral cleft alveolus and palate defect skull and check the dimensional changes in the maxilla, which will be useful for the clinicians.

## 2. MATERIALS AND METHODS

Ethical clearance approval for this research was obtained from SRM Medical College Hospital & Research Center with ethical clearance number: 853/IEC/2015. A 3-D FE model of a human skull with the complete left-sided unilateral cleft lip, alveolus and palate was produced based on CBCT scan data of a 26 year old male with complete left sided unilateral cleft lip, alveolus and palate. CBCT was obtained using Kodak 9500 with slice thickness 0.3 mm and slice increment 0.3 mm. The scan matrix size is  $665 \times 665$  and field of view is 199.50 mm. The scan provided 600 slices of 2D data.

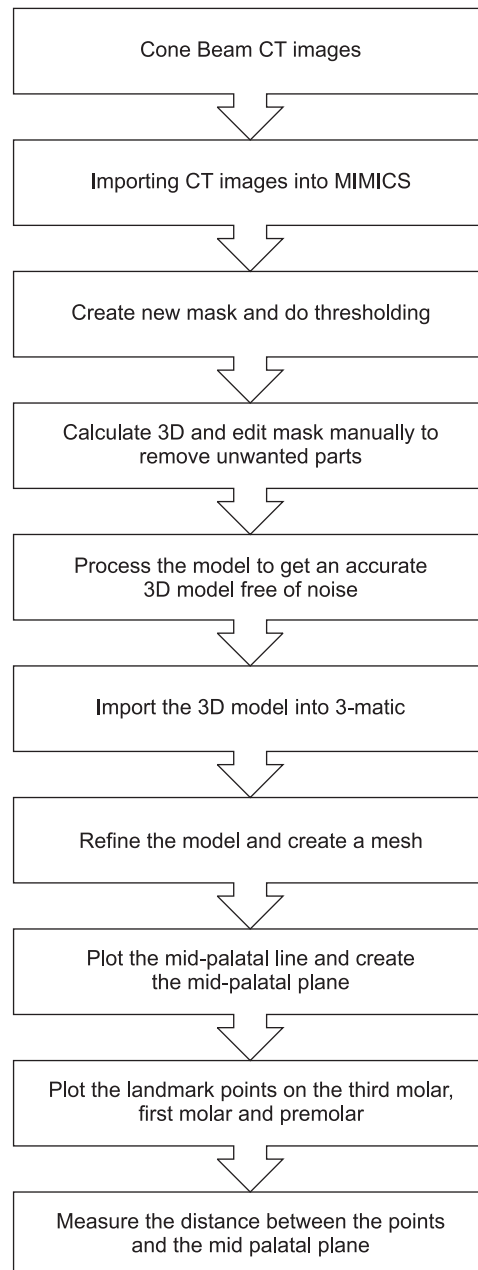
Figure 1 shows the workflow carried in constructing the FE model. The CT images are available in Digital Imaging and Communications in Medicine (DICOM) format, which is the input to MIMICS<sup>®</sup> software (Materialise, Belgium) for model reconstruction. The original sectional data was represented as 3D by using volume rendering model. The hard tissue separated from soft tissue by choosing a proper threshold based on tissue density. The CBCT, which has an inherent disadvantage that the Hounsfield Unit (HU) are not the same in all the slices. Thus it requires a long manual segmentation steps to segment the bone tissue. The noisy pixels that fall in the threshold limit which is in the soft tissue region. The noise region was removed using region growing method. The pixels which are connected retained in the mask and the rest of the pixels are removed. The pixels which are not in the bone part is removed manually by editing the mask.

Teeth was segmented separately and included in the 3D model. The Boolean operation was used to unify the mask of the individual tooth into single mask before constructing the 3D model. The small gaps are closed in the model and the wrap option is used and to remove noise and spikes, smoothing was done for ten iterations of the model.

The created 3D model with triangular elements is exported into 3-matic (part of MIMICS innovation suit) a FE preprocessing software in which surface mesh is refined and a volume mesh with tetrahedral elements are generated. On the surface mesh local smoothing was carried to remove sharp and spike triangles that violated maximum angle. Remesh was carried to restrict the shape measure above 0.3, measure used was height/base. Finally, quality preserving triangle reduction was done to reduce the number of triangles in the surface mesh.

To get the measurements in the maxilla, a mid-palatal plane was created. A midpoint was located in the line constructed between the disto-palatal cusp tips of both side third molar teeth. A point is placed in the deep most anterior border of foramen magna. Both these points were connected forming a mid-palatal plane and is extended till the nose. Points on the Mesio-palatal cusp tips of first and third molars, and palatal cusp tips of the first premolar on both sides were located for maxillary dimension measurements. A line (coronal plane) parallel to the inter-third molar line passing through the contact point between the

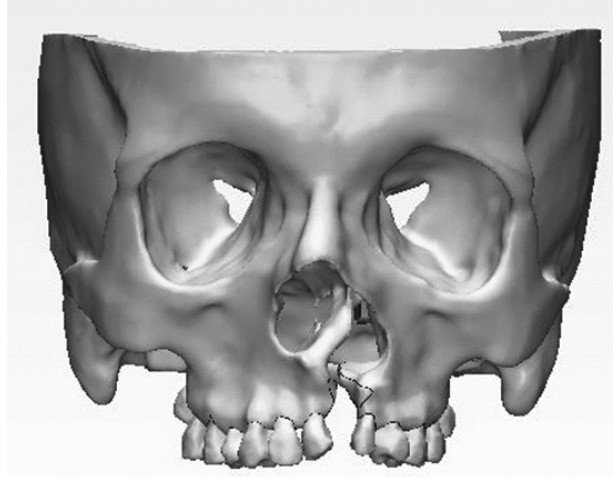
right side second premolar and first molar was constructed extending to the left side for antero-posterior assessment.



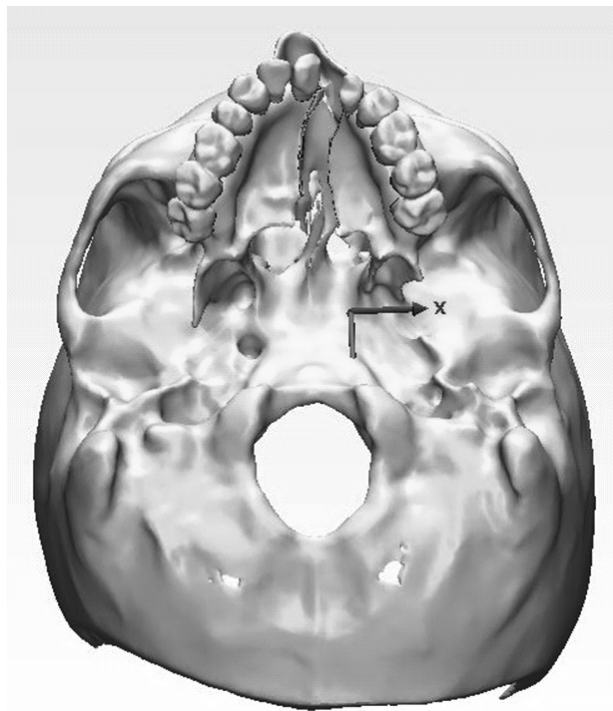
**Figure 1: Workflow**

### 3. RESULTS

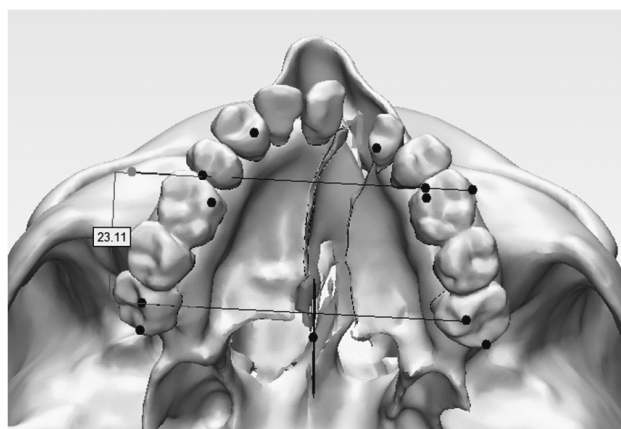
Figure 2 shows the view of the created model with complete unilateral cleft alveolus and palate. The vertical septum in the nasal cavity is deformed and attached to the non-cleft side instead of its midline position. The left side segment is the cleft side and is the minor segment and right side is the major segment. The model has only 12 maxillary teeth (instead of 16 teeth), due to cleft some teeth were missing congenitally. Figure 3 shows bottom view of the model and the cleft gap is 6.30 mm at the alveolus, 7.15 mm at mid palate and the maximum at the end of palate 10.75 mm. Figure 4 shows the model with the coronal line for antero-posterior displacement. Figure 5 shows the measurements recorded on the maxilla.



**Figure 2: View of created model**



**Figure 3: Bottom view of the model showing cleft**



**Figure 4: View of the model with coronal line for antero-posterior displacement**

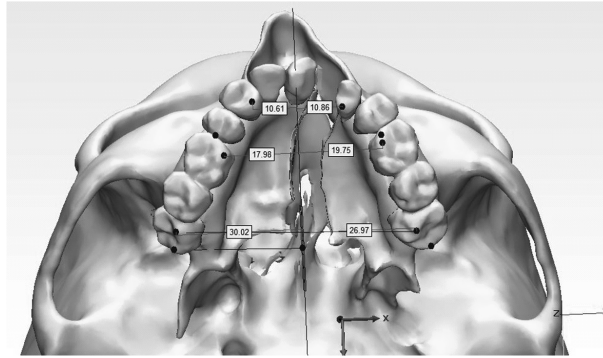


Figure 5: View of measure between first and third molars

#### 4. DISCUSSION

Finite element model of a complex structural deformity of a human skull was successfully done. This model is of an adult with unrepaired cleft and palate. Teeth is present in the sockets in the skull which creates an intersecting mesh between teeth and skull as they were modeled separately. To get the final model with the nodes matching at intersecting surfaces an assembly between teeth and skull was created to ensure the nodes match and there is effective stress transfer during simulations. Such modeling will allow clinicians to simulate clinical conditions 3-dimensionally which will be useful in the diagnosis and treatment planning. Accurate real-time measurements can be done in the FE model as it is constructed from the patient's CT scan. In our study, we measured the maxillary dimensions in the transverse and antero-posterior planes as the maxilla is deformed 3-dimensionally. From the reference lines constructed as said in the methodology, the following maxillary measurements were recorded. The inter-third molar width on the right was 30.02 mm and on the left it was 26.97 mm. The inter-first molar width on the right was 17.98 mm and on the left it was 19.75 mm. The inter-premolar width on the right was 10.61 mm and on the left it was 10.86 mm. In the posterior maxilla, the non-cleft side is wider, in the mid maxilla the cleft side is wider and in the anterior region it is symmetrical. The cleft side maxilla is also placed anterior compared to the non-cleft side as measured from the coronal line. These measurements will help the clinicians to achieve symmetry while doing the reconstructive surgery and orthodontic therapy. Symmetry is important for function and esthetics in the human face and skull.

Athanasiou A.E et.al [7] carried a study by comparing the dental arch dimensions of 72 children with unilateral cleft lip and palate with that of normal children. The width of the first molar with a mean value 39.72 and width at premolar 32.13 mm for 12 years age group. This clearly brings out that maxilla width varies within molar, premolar and canine regions in cleft palate patients.

#### 5. CONCLUSION

A 3D FE model was created for a complex craniofacial anomaly using CBCT images. The model successfully provided a base to carry out clinical oriented analysis that are not possible to do 3-dimensionally, as done in the maxilla in this patient. There is considerable asymmetry in the maxilla and cleft sided is anterior compared to non-cleft side. This 3D modelling brings a possibility to study the changes in a level that is not possible by conventional studies.

Table 1  
Lateral dimensions of Maxilla

<i>Measurement</i>	<i>Right (mm)</i>	<i>Left (mm)</i>
Inter third molar width	30.02	26.97
Inter first molar width	17.98	19.75
Inter premolar width	10.61	10.86

### References

1. Tim Goodacre Marc C Swan; “*Cleft lip and palate: current management.*” PAEDIATRICS AND CHILD HEALTH 18:6, 2008.
2. Boyne PJ, Sands NR, “*Secondary bone grafting of residual alveolus and palatal clefts.*” Oral Surg. 1972; 30: 87-92.
3. P. Mossey , E. Castilla, “*Craniofacial anomalies and associated birth defects, Global registry and database on craniofacial anomalies*”, Report of a WHO Registry Meeting on Craniofacial Anomalies, Bauru, Brazil, 4-6 December 2001
4. K. Ujigawa, Y. Kato; Y. Kizu, M. Tonogi; G.-Y. Yamane. “*Three-dimensional finite elemental analysis of zygomatic implants in craniofacial structures.*” International Journal of Oral Maxillofacial Surgery 2007; 36: 620–625
5. Pawan Gautam; Linping Zhao; Pravin Patel. “*Determining the osteotomy pattern in surgically assisted rapid maxillary expansion in a unilateral palatal cleft A finite element model approach.*” Angle Orthodontist, Vol. 81, No. 3, 2011
6. Yasuo Honda, Akira Suzuki, Masamichi Ohishi, Hideo Tashiro. “*Longitudinal Study on the Changes of Maxillary Arch Dimensions in Japanese Children with Cleft Lip and/or Palate: Infancy to 4 Years of Age*” The Cleft Palate-Craniofacial Journal, Vol. 32, No. 2,1995.
7. Athanasiou AE, Mazaheri M, Zarrinnia K. “*Dental arch dimensions in patients with unilateral cleft lip and palate.*” Cleft Palate Journal, 1988 Apr; 25(2):139-45.
8. Dan Zhang, Li Zheng, Qiang Wang, Li Lu and Jia Ma. “*Displacements prediction from 3D finite element model of maxillary protraction with and without rapid maxillary expansion in a patient with unilateral cleft palate and alveolus*”. BioMed Eng OnLine (2015) 14:80.