



## International Journal of Control Theory and Applications

ISSN : 0974-5572

© International Science Press

Volume 9 • Number 49 • 2016

### Extracting Exudates from Retinopathy images using Morphology

<sup>1</sup>S. Deva Kumar, <sup>2</sup>N. Ganeswara Rao, <sup>3</sup>T. Sravani and <sup>4</sup>V. Hiranmai

<sup>1</sup> Asst. Professor, Dept. of CSE, VFSTR University, E-mail: deva.248@gmail.com

<sup>2</sup> Professor, Dept. of CSE, VFSTR University

<sup>3</sup> Software Analyst, MLIT Solutions

<sup>4</sup> Dept. of CSE, VFSTR University

**Abstract:** Diabetes enhances the risk of destruction of blood vessels that pumps blood to the retina an ailment known as Diabetic Retinopathy (DR). Since this disease does not show any symptoms it can only be diagnosed by ophthalmologist. However, the number of ophthalmologists coming up is less than the people with diabetes so that tracking and diagnosis in early stages is difficult due to the lack of opportunity in terms of time and cost. The presence of exudates is the basic signs of DR. Hence, identification of exudates becomes a major problem solving task, in which retinal images plays a very important role. If this is detected in early stage, it is very much useful to the ophthalmologist to treat the patients in avoiding the blindness of the patients by their treatment. This paper proposed a technique based on morphological operations and adaptive thresholding to identify the exudates from Diabetic Retinopathy retina images. At the preliminary step, the input image i.e. retinal image should be preprocessed, where at first the RGB color space is turned into the HSI color space and based on the extremity values of HSI color space wiener filter is applied to remove noise and then histogram equalization is done to regularize the image. In the subsequent stage, exudates are detected using morphological closing operation and then Adaptive thresholding is done. On evaluating the results, the proposed method got better performance than the existing method.

**Keywords:** Diabetic Retinopathy; Retinal Image; HSI Image; Average Filter; Histogram Equalization; Morphological Closing Operation; Adaptive Thresholding Method;

#### 1. INTRODUCTION

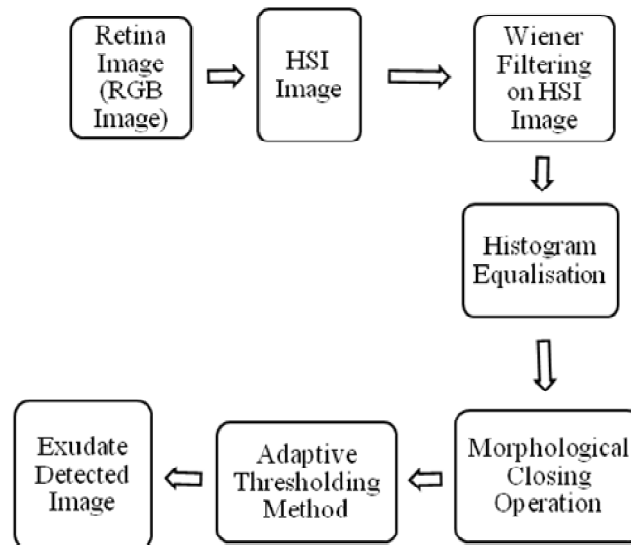
The common effect of vision loss in people is because of diabetes which is the Diabetic retinopathy and mainly leads to blindness among elders who are working. Human with diabetes are at danger for causing diabetic retinopathy. Disease increases when someone has diabetes for longer time. Among all the Americans diagnosed with diabetes have certain phase of diabetic retinopathy which is about 40-45 percent, out of them only about partial are aware of DR. Women who are having diabetes in the course of pregnancy may have quick effect of diabetic retinopathy.

When someone has high blood sugar levels, the blood vessels in the retina can become damaged, So that it can be prevented through frequent checkups and treatment, and proper follow-up on diabetic eye disease can

check against vision damage. Therefore, by early recognition reduces the severity of the disease [1]. In processing of a retinal image, fundus images are used for primary analysis of diseases. For disease analysis, the best method is to take victim's retina image between a definite time intervals and match those images to realize the variations in the retinal image [2]. The segmentation of retinal image structures [3] is the major part of this paper, which is used for analysis by modern eye doctor. The morphological closing operation on the exudates is a vital structural operator for evaluating the occurrence and severity of the disease [17]. The inspection on the retinal image is done by the percentage of exudates obtained, after applying the morphological closing operation which lets eye care specialists to perform vision checkups for early detection of disease [18,19]. This could reduce vision loss; in addition it reduces the charge of the screening.

## 2. METHODOLOGY

The projected procedure detects exudates in retinal image using the concepts of morphological and adaptive thresholding methods. In the whole process, the exudates are detected using mathematical morphological operation and adaptive thresholding. In this projected technique, the entire proposed methodology is shown in Block Diagram 1.



Block Diagram 1: Proposed Technique

### (a) Retina Image

The first step in the image examination is to take input as retinal image as shown in Fig 1. Image capturing is done normally by a digital camera which is an embedded digital camera at the back. The digital camera works in the same way as a normal camera works, only differentiation is that digital fundal camera embedded with an image sensor.

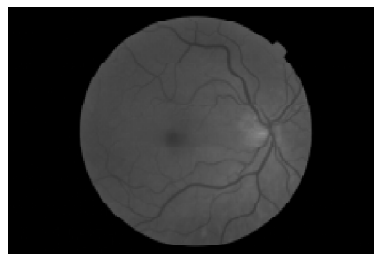


Figure 1: DR Fundus Image

**(b) HSI Image**

Initially, the original given retinal image which is in RGB color format, is converted to HSI format (where, H is Hue, S is Saturation and I is Intensity) as shown in Fig. 2.

The fundus image which is in RGB color is transformed to HSI image [4,5] and as gray level values of exudates are high, so intensity band of HSI image is used to further procedure [6]. The translation of RGB color format to HSI format is straightforward way [7].

The formulas for finding HSI components are given below:

Hue (H) is defined by

$$H = \begin{cases} \theta & B \leq G \\ 360 - \theta & B > G \end{cases} \quad (1)$$

Where,

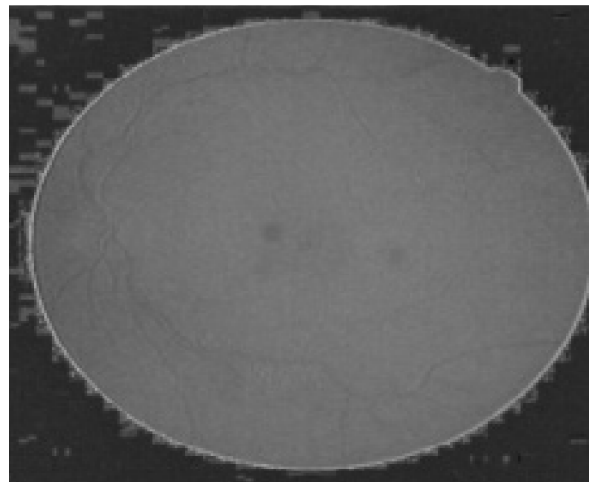
$$\theta = \cos^{-1} \left\{ \frac{\frac{1}{2}[(R-G) + (R-B)]}{[(R-G)^2 + (R-B)(G-B)]^{\frac{1}{2}}} \right\} \quad (2)$$

In HIS, Where S is Saturation and it is defined by

$$S = 1 - \frac{3}{[R+G+B]} \min(R, G, B) \quad (3)$$

Where I is Intensity and it is defined by

$$I = \frac{1}{3}(R+G+B) \quad (4)$$

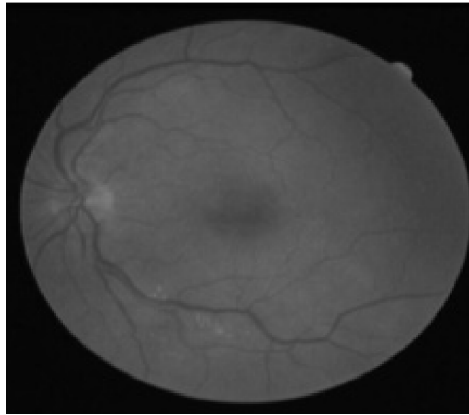


**Figure 2: HSI Image**

### **(c) Applying Wiener Filtering on HSI Image**

The nonlinear method Wiener filtering decreases the noise. The noise that is taking place in a communication channel is because of random bit error [8]. In this filtering, a window is slid on every pixel of the image, and the intensity values of the pixels inside the window yields the intensity of the output pixel being processed.

Then in the next step, average filtering is applied on the intensity band (I component in HSI space) of the image for noise removal [9] as shown in Fig 3.



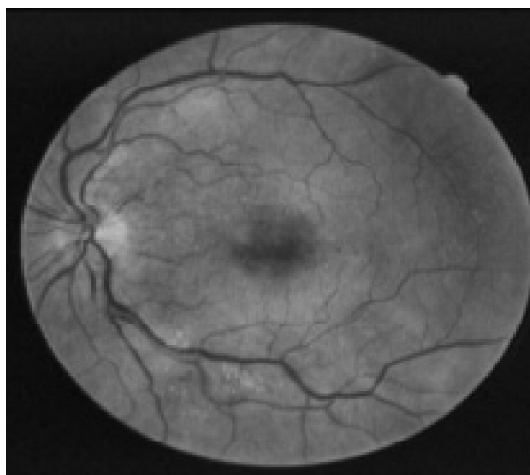
**Figure 3: Wiener Filtered Image**

### **(d) Histogram Equalization**

Histogram equalization is a method which uses the image's histogram for contrast adjustment. This method raises the overall contrast of an image, mainly when the important data of the image is shown in low contrast values. The intensities of the pixels can be better scattered on the histogram through this histogram equalization [10]. This method is useful when both background and foreground of an image are bright or dark.

In this process, adaptive histogram equalization [11] is used and then the procedure divides the image into regions and then histogram equalization is applied to each region.

Then in the subsequent step, the histogram equalization is applied for image enhancement to avoid the saturation in the retina image of similar areas [12] as shown in Fig 4.



**Figure 4: Histogram Equalized Image**

## (e) Detection of Exudates

### 1. Morphological Closing Operation

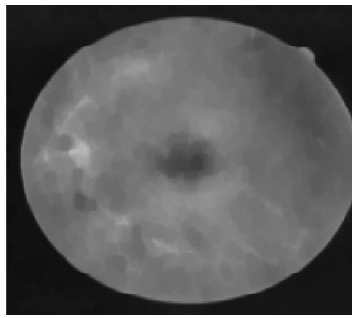
One among the group of non-linear operations is Morphological closing operation in image processing [13] is linked to the shape of an image. Morphological procedures detect an image with a shape which is known as a structuring element. The morphological closing operation of an image is applied by a structuring element where a dilation operation is applied followed by an erosion operation is performed as:

$$f \bullet s = (f \oplus s_{\text{rot}}) \ominus s_{\text{rot}}$$

Where  $f$  is an image and  $S$  is a structuring element.

In this step, the morphological closing operation [14] along with a structuring element i.e. an optic disc shaped structured element is applied on the preprocessed image [15] and then the subsequent resultant image is binarised by the Adaptive Threshold method.


In our projected technique, Fig 5 shows the subsequent image by removing the high contrast blood vessels on applying the morphological closing operation with a flat disc structuring element. Then, the exudates are to be detected in the retinal image which are considered as the largest circular related components, and the further step i.e. Thresholding technique is applied.



**Figure 5: Morphological Closing Operation Image**

### 2. Adaptive Thresholding

Thresholding is the easiest way to segment objects from a background. Based on the background value is somewhat relatively uniform then it can be used for a global threshold value to binarize the retinal image. Suppose the background value is more variations of intensity, then the adaptive thresholding may generate good results. After to apply binarize an image using the adaptive threshold function then it calculates thresholds in regions of size blocks of each surrounding pixel. The each threshold value is calculated weighted mean of the local neighborhood subtracted to an offset value as shown in Fig. 6.



**Figure 6: Adaptive Threshold Image**

Then the resultant image obtained in Adaptive Thresholding is superimposed the thresholded image onto the original image for showing the exudate detected as shown in Fig 7.

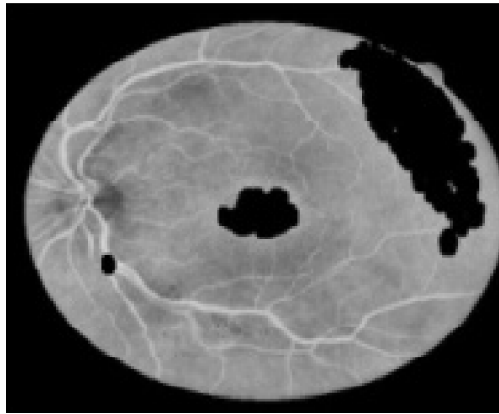


Figure 7: Exudate detected Image

### 3. RESULTS

From the reference number [16] which is the existing method is varied from my projected method i.e. in the existing method they used median and Gaussian filters whereas in the projected method used only wiener filter. By doing so the percentage of exudates detected varies as shown in below Table 1:

**Table 1**  
Results of Diabetic Retinopathy between Existing Method and Proposed Method

Image Number	Percentage of Exudates in the Existing Method (%)	Percentage of Exudates in the Proposed Method (%)
Retinal Image1	39.97	39.99
Retinal Image2	37.06	37.19
Retinal Image3	38.32	38.41
Retinal Image4	37.36	37.47

### 4. CONCLUSION

The proposed method is an innovative procedure to detect exudates by means of morphological closing operation and adaptive threshold method along with more noise suppression with the use of wiener filter. In this whole process, the I-band of HSI image is used and as more noise involves in the fundus image, various pre-processing procedures are applied for removing the noise and for enhancing features using adaptive histogram equalization to equalize all the regions in an image for showing irregular contrast. This procedure can be applied to every retinal image. The percentage of the exudates detected is 39.99%.

### REFERENCES

- [1] S. Sekhar, W. Al-Nuaimy and A. K. Nandi "Automated Localisation of Optic Disk and Fovea in Retinal Fundus Images" 16th European Signal 2008.
- [2] AlauddinBhuiyan, BaikunthNath, Kotagiri Rama mohanara and Tien Y. Wong "Retinal Image Matching Using Hierarchical Vascular Features" The University of Melbourne, VIC 3002, Australia.
- [3] Jayakumari, C., Santhanam, T.: 'Retinal blood vessel segmentation for assessment of diabetic retinopathy using a two-dimensional model', Asian J. Inf. Technol., 2007, 6, (12), pp. 1205-1211

- [4] Maureen C. Stone (August 2001). "A Survey of Color for Computer Graphics". Course at SIGGRAPH 2001.
- [5] Keith McLaren; "Dyes, General Survey" in: *Ullmann's Encyclopedia of Industrial Chemistry*; Wiley-VCH; 15 June 2000.
- [6] Sopharak, A., Uyyanonvara, B., Barman, S., Williamson, T.H.: 'Automatic detection of diabetic retinopathy exudates from non-dilated retinal images using mathematical morphology methods', *Comput. Med. Imaging Graph*, 2008, 32, (8), pp. 720–727
- [7] N Ganeswara Rao, V Ramakrishna Sajja, S Deva Kumar and M Venkata Rao "An Improved IHBM using Smoothing Projections" Vol.8, No.1, Jan-June 2015, Pp.326-335.
- [8] Naga Mahesh kundeti, Hemantha Kumar Kalluri, S V Rama Krishna "Image Enhancement Using DT-CWT Based Cycle Spinning Methodology".
- [9] Kirchner, M., Fridrich, J.: 'On detection of median filtering in digital images'. *Proc. SPIE – Int. Society for Optical Engineering*, 2010, 7541, pp. 754110.
- [10] Kumari, V.V., Narayanan, N.S.: 'Diabetic retinopathy – early detection using image processing techniques', *Int. J. Comput. Sci. Eng.*, 2010, 2, (2), pp. 357–361.
- [11] Kavitha, S., Duraiswamy, K.: 'Automatic detection of hard and soft exudates in fundus images using color histogram thresholding', *Eur. J. Sci. Res.*, 2011, 48, (3), pp. 493–504.
- [12] Vij, K., Singh, Y.: 'Enhancement of images using histogram processing techniques', *Int. J. Comput. Technol. Appl.*, 2011, 2, (2), pp. 309–313.
- [13] An Introduction to Morphological Image Processing by Edward R. Dougherty, ISBN 0-8194-0845-X (1992).
- [14] "Appendix A: The 'Centre de Morphologie Mathématique', an overview" by Jean Serra, in (Serra *et al.* (Eds.) 1994), pgs. 369-374.
- [15] Maragos, P., W.Schafer, R.: 'Morphological systems for multidimensional signal processing', *Proc. IEEE*, 1990, 78, (4), pp. 690–719.
- [16] Nayomi Geethanjali Ranamuka, Ravinda Gayan N. Meegama Department of Statistics and Computer Science, Faculty of Applied Science, University of Sri Jayewardenepura, Nugegoda, Sri Lanka IET Image Process., 2013, Vol. 7, Iss. 2, pp. 121–130 doi: 10.1049/iet ipr.2012.0134 'Detection of hard exudates from diabetic retinopathy images using fuzzy logic'.
- [17] N Ganeswara Rao, V Ramakrishna Sajja, S Deva Kumar and M Venkata Rao, "An Improved IHBM using Smoothing Projections", *International Journal of Control Theory and Applications*, 2015, Vol.8, Iss 1, pp. 326-335.
- [18] Automated detection of Optic Disc for the analysis of retina using color fundus image; M. Zubair ; Dept. of Comput. Eng., NUST, Rawalpindi, Pakistan ; A. Yamin ; S. A. Khan; Published in: *Imaging Systems and Techniques (IST)*, 2013 IEEE International Conference.
- [19] Ganeswara Rao, N., Sravani, T., Vijaya Kumar V, "OCRM: Optimal cost region matching similarity measure for region based image retrieval", *International Journal of Multimedia and Ubiquitous Engineering*, Vol.9, No.4 (2014), pp. 327-342.