

An Empirical Study of Image Processing Techniques for the Diagnosis of Glaucoma from Optical Coherence Tomography and Fundus Images

M. Hemalatha* S. Nithya**

Abstract : Glaucoma is one of the second leading cause of blindness in India. It cannot be cured when it doesn't presage in an accurate time. 90% of people have never been diagnosed before in India. According to the World Health Organization statistics, one in eight persons above the age of 40 getting are affected from Glaucoma or lead to cause of death. It can be diagnosed by two types of images such as Optical Coherence Tomography and Fundus images for early detection and to prevent the loss of vision. It is mainly used for analyzing the disease or tissue structure which is very useful for doctors to get clear idea about biomedical image. This paper presents the latest survey for diagnosing Glaucoma by using proposed image processing techniques in various stages such as Preprocessing, Image Resizing, Feature Extraction, Segmentation and Classification which are used frequently, it will be more useful for research persons for doing their research in Glaucoma. The deliberate research work is to detect accurately and monitoring its progress quickly.

Keywords : Optical Coherence Tomography, Noise removal, Image resizing, Feature Extraction, segmentation, Classification, Compression.

1. INTRODUCTION

Glaucoma is a dangerous disease which affects the Eye's optic nerve and lead to loss of vision due to the high pressure in the eye. In India, Nearly 12 millions of people were getting affected by glaucoma without knowing the symptoms until the disease become dangerous. In glaucoma the retinal ganglion cell does not die in early stages of the disease. But its death is quite delayed in the disease process .The most two important type of glaucoma, one is Primary open angle glaucoma which is affected by across 7 million persons and other is Primary angle closure glaucoma is estimated as 4 million people in India. It is mainly affects because of the increasing eye pressure level. 23% of people were become blind in either one or both eyes due to glaucoma. It is mainly affected by the people over 40 years old and including new born babies. Other types of Glaucoma are Secondary, Pigmentary, Normal Tension, Congential, Exfoliative, Neovascular, Traumatic Glaucoma. The treatment can be given based on the type of glaucoma. Women were suffering from three times higher risk than men. Hence a people increase as well as glaucoma is also increases which become a serious public health concern. Early identification is the first step to stopping the action of disease. By using Optical Coherence Tomography and fundus images is non enveloping has been widely used for many medical imaging applications, mainly in Ophthalmology for diagnosing Glaucoma. To develop Clinical analysis, Ophthalmologists often need high clarity spatial resolution by using both OCT and Fundus images. It is the basic step for diagnosing the disease. Preprocessing is used

* Dean Science, School of Computer Science, Dr. SNS Rajalakshmi College of Arts and Science, Coimbatore-49, India

** PhD Research Scholar, School of Computer Science, Dr. SNS Rajalakshmi College of Arts and Science, Coimbatore-49, India

for removing the unwanted noise in the image by using various filters. Image resizing is the process of changing the size of the image without changing the number of pixels in the image. Image segmentation is the process of separating a digital image into various set of pixels segments. After segmenting an image, the classification process is to differentiate all pixels in a digital image into one of several land cover classes. Finally image compression is to reconstructing an original image without affecting the quality of the original image.

The remaining part of this paper is discussed as follows. Section II describes the review of literature; followed by section III includes Comparative analysis of the existing system. Finally, section IV concludes and goes through the future work.

2. LITERATURE REVIEW

In this section, the OCT with fundus retinal based image on glaucoma research using image processing techniques as preprocessing, extracting the features and resizing the image, segmentation and classification. Finally, the future research is discussed in this section.

A. Image Preprocessing

Vishali Kakada and Swati Madhe et.al [1] In this paper the proposed work is detecting vessels and suppressing the noise in the OCT images. It is used for defining cross sectional medical images. Here images are despoiled by random variations or have bad disparity is called noise. To minimize the noise in OCT images they had used various filters such as Gaussian filter, Wiener filter, Median filter and Average filter. OCT images are taken from H.V.Desani Eye hospital they worked with 50 images. The resolution of an image is 512*512 pixel. Objective evaluation measures are calculated and compared by using PSNR, MSE and RMSE. Finally the comparison results show that median filter provides good PSNR value and it is significantly reducing the noise in the affected images.

Alexander wong et.al [2] “This paper describes reducing the speckle noise in OCT by using General Bayesian estimator. It is multiplicative to notify this, noise reduction algorithm had been developed. It depict the imaging data into logarithmic space and general Bayesian least square estimate approach sand then images were tested with the ultra high resolution system. They developed a new novel algorithm for removing the speckle noise in OCT images based on Bayesian estimation. It determines superior noise suppression and detail preservation. They had used different evaluation measures such as SNR, contract to noise ration, edge preservation and equivalent number of 100k measures. The merit of using this algorithm is to show elevated contrast and very sharp look of unique image. Finally the SNR value shows that improvement of 17db when comparing with the other method.

N.Padmasini, K.S. Abbirame et.al [3] This article describes how to reduce the speckle noise by using fuzzification and Anisotropic diffusion filtering” SDOCT is used to detecting and scheming the level of disease. Speckle noise is found in SDOCT image. They had used anisotropic diffusion filtering for effective reduction in speckle noise and they removed 2-3micron of noise. Here the pixel value of the original image is (500,150). By using anisotropic diffusion filtering the noise had been removed and the result is compared with the peak signal to noise ratio. The value is 10.67db and it shows good results when comparing with the other method. The PSNR value is increased about 64.5db on an average and this filter enhances the image by preserving its edges.

Chandrappa.S, Dharmanna Lamani et.al [4] The Retinal Nerve Fiber Layer thickness is the most scientific parameter for identifying the Glaucoma eye disease. Preprocessing is the most important part to take away the noise by using median filter algorithm for removing the unwanted noise.

Markus A. Mayer, Anja Borsdorf et.al [5] Speckle noise have been removed by using wavelet decomposition of the one frame for a simple noise and estimating the structure. Each frames are weights are estimated. They had proposed two weights, significant and correlation weight The detailed wavelet coefficients are measured with the averaged weights and distorted back. Reducing the noise can be

corrected with the consideration. A signal-to-noise gain of 101.2% which leads to a sharpen the image calculated by full-and half width reduction of 10.5%. The experimental results shows that noise had been reduced effectively without affecting the image.

B. Image Resizing and Feature Extraction

In [6] different extraction methods including Pixel Intensity Value, Textures, FFT Coefficients Pixels intensity and Histogram Model were used to identify feature like luminance, translation invariance, papilla rim, cup size. P-tile threshold method was used to identify features like Color and shape in [7]. In [8] Macular Cube algorithm was used to extract features like macula thickness. Designed sequential FMM in painting method modules was used to identify features like cup to disc ratio, neuro retinal rim configuration, and vessel distribution information in [9].

A. Rajan and G.P. Ramesh et.al [10] In this paper features are taken from the OCT images in the continuous domain by using wavelets. OCT images are turned to DWT decomposition and it is evaluated as features. The image size is 64x128 it means 8192 wavelet coefficients offered as features. It is a bulk data and it demonstrates the correctness and it consumes more time. To triumph over this problem study t-test class separability criterion is applied for feature selection and used to classify the affected and unaffected images in the OCT.

Yogesh and Sasikala explained the texture analysis of the retinal fiber layer in spectral domain OCT images to predict the disease [11]. SD-OCT images was viewed with the fluid filled regions retinal disorders. It is used to differentiate the surface and feature extraction. 22 Texture feature is used for classification. If the feature value exceeds the preset normal range, it indicates abnormal image. Finally, SD-OCT is used for diagnosing the disease.

C. Segmentation

Dhivyabharathi, Ganeshbabu et.al [13] In this paper affected and unaffected images are taken, RNFL is measured for identifying the glaucoma disease. Gabor filter is used for segmenting the texture for retrieving all the layers in the image and an algorithm is developed to segment the RNFL. The measurement of RNFL is automatically visualized based on the pixel calculation. Then the resulted value is compared with the original imagers taken from the hospital. Finally the results show that proposed algorithm is efficient for segmenting the region of interest without the manual calculation.

Chandrappa.S, Dharmanna Lamani et.al [4] RNFL is segmented by using statistical region merging algorithm and then it is modified by using morphological operations such as dilation and erosion. The proposed work is tested with the 50 RNFL images. Finally it shows higher potential for estimating the retinal layer thickness. It is used to easily find the thickness for detecting the Glaucoma disease.

Dominic Williams, Yalin Zheng et.al [14] presented novel graph technique is used for regional and shaping. Segmenting can be done using 39 OCT images. When comparing with the manual segmentation mean DSC value of 0.943 ± 0.020 was performed. It is very fast and accurate. This technique is used to produce an input for patient specific biomechanical models of the human eye.

R. Nithya, N. Venkateswaran et.al [15] presented Segmentation is used for detecting Glaucoma by using both fundus and OCT images and comparison results is found. Segmentation is used for differentiating the Optic disc and cup and the diameter are measured for separating RNFL and RPEL. The fault of the fundus image and the OCT image investigations were balanced and the results are produced. From the new results, it is naturally state that the diagnosing glaucoma can be done in alternative way by using the OCT image analysis. The deformation happens in the cup region due to glaucoma which can be monitored more correctly in the OCT images as it gives the layer information of the retina.

Azadeh Yazdanpanah, Ghassan Hamarneh et.al [16] described the semi automated segmentation algorithm is used to detect intra retinal layers in OCT images. This technique was succeeded by an average Dice similarity coefficient of 0.84 over all segmented retinal layers and of 0.94 for the joined nerve fiber, ganglion cell, and inner plexiform layers which is the most difficult layers for degenerating the glaucoma.

D. Classification

Dimitrios Bizios, Anders Heijl et.al [17] RNFL thickness was calculated by using Optical Coherence Tomography for detecting the initial stage of Glaucoma. They had taken nearly 150 patient data and it was tested by using Machine Learning Classifiers, Artificial Neural Network and Support Vector Machine classification techniques. Classifier area under the receiver operating character curve (AROC) was manipulated. The AROC's of ANN (0.982, 95% CI: 0.966–0.999) and SVM (0.989, 95% CI: 0.979–1.0). There was no main difference between ANN and SVM. Hence both MLCs performance was good with the slight diagnostic performance. So, RNFL was processed by machine classifiers which is used to improve OCT-based glaucoma diagnosis.

Soe Ni Ni, J. Tian et.al [18] Glaucoma SS-OCT images are classified by using anterior chamber angle shape analysis. Optical Coherence Tomography is the most important tool for angle closure glaucoma. Here fuzzy k nearest neighbor classifier is to make use of identifying the angle closure glaucoma. 264 SS-OCT images had been collected from nearly 148 patients. By using parametric biometer, fractal analysis and finally classification by fuzzy kNN technique is to maintain the good accuracy rate which was 98.11%. Hence the results showed that the new approach has quite potential to become a computer aided identifying tool for angle closure glaucoma disease.

A.Rajan, Ramesh G.P et.al [19] In this paper they had used three classifier such as Naïve Bayes, k-Nearest Neighbour and Support Vector Machine for predicting the glaucoma disease. The experimental results shows that SVM classifier achieves good results when comparing with the NB and KNN. The accuracy rate is 90.75%, and this proposed work yields sensitivity of 91.79% and specificity of 89.71%.

N. Anantrasirichai, Alin Achim et.al [20] This paper is used for detecting the Glaucoma by using retinal OCT. Classification has been done by using Support Vector Machine with the improvement of Principal Component Analysis. The thickness of the inner layer and texture are organized. Finally the results shows that texture features can be improved by using SVM classification accuracy is 4% .

Susanna Ricco, Mie Chen et.al [21] “Classification of scan location in retinal OCT” Spectral domain OCT is a tool for diagnosing the Glaucoma. In this work efficient automated classification technique is used for differentiating the specific scan type. This algorithm distinguishes between the presence and absence of vessels which joining on the optic disc. They had tested the algorithm with 1015 scans of both normal and abnormal patients report. Finally by using Matlab the sensitivity of 100% and Specificity of 99.7%. This classifier is most secure to retinal pathologies and provide particular results suffering from Glaucoma.

E. Image Compression

Image compression is mainly used to minimizing the storage space without affecting the image Quality and also to store or transmit the data in an easiest way. When the file size is reduced it allows many images to be accumulated in a given amount of disk or memory space. It also minimize the time for sending the images over the Internet or downloaded from Web pages. OCT In medical imaging human eye images can be converted into digital form. At the same time it consumes large amount of data storage for communication purposes. There are huge number of compression techniques are available for reducing the data size with minute loss of image quality. On the other side in medical imaging it may be very necessary to maintain perfect quality of the image only in the region of interest, *i.e.*, in diagnostically important regions.

Most of the glaucoma OCT images are used for classification or segmentation for diagnose the disease. For storage and communication purposes the image compression is focused for future research.

3. COMPARATIVE ANALYSIS OF THE EXISTING SYSTEM

This paper work describes the survey of latest image processing techniques for diagnosing the Glaucoma. The above review based techniques and performance results are evaluated using MATLAB version 12.

The images are taken from <https://sites.google.com/site/hosseinrabbanikhorasgani/datasets-1>. The green channel is the optimal option to be processed for the OCT and fundus retinal database. This dataset contains OCT data (in mat format) and color fundus data (in jpg format) of left & right eyes of 50 healthy persons.

The performance of vessel segmentation is analyzed with the following parameters :

$$\text{Sensitivity} = \text{TP}/(\text{TP} + \text{FN})$$

$$\text{Specificity} = \text{TN}/(\text{TN} + \text{FP})$$

$$\text{Accuracy} = (\text{TP} + \text{TN})/(\text{TP} + \text{FN} + \text{TN} + \text{FP})$$

Where, TP denotes true positive, FP denotes false positive, FN is false negative and TN is true negative. True Positive refers to the correctly identified disease, True Negative refers to the wrongly identified disease, False Positive refers to the correctly identified background pixels and False Negative refers to the wrongly identified background pixels.

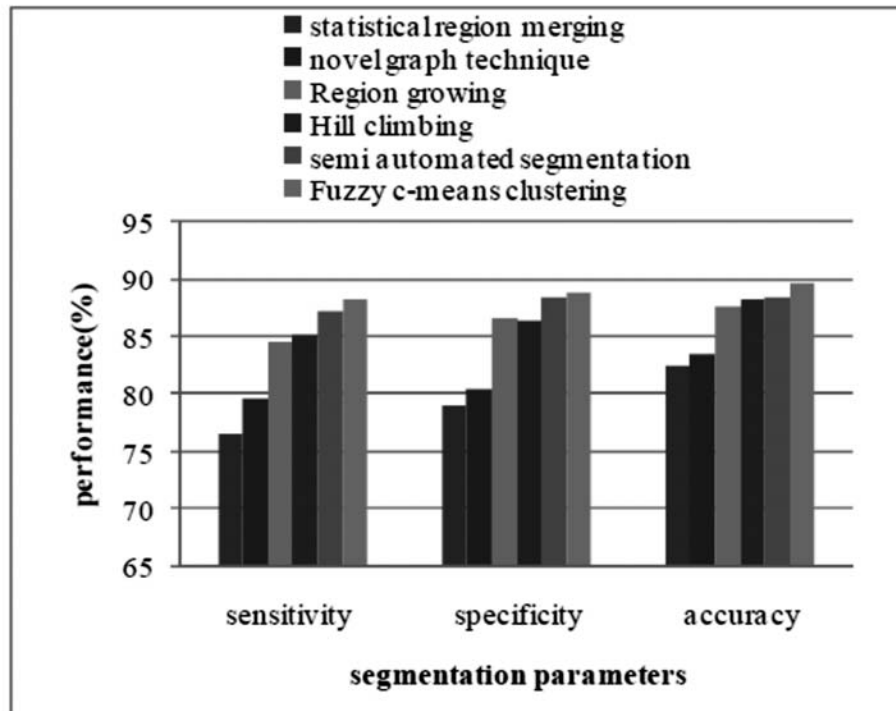


Figure 1: Graphical Representation of Performance Parameters of glaucoma segmentation methods

Fig 1 shows the performance evaluation of existing segmentation algorithms was analyzed based on the parameters such as sensitivity, specificity and accuracy. It clearly shows that the fuzzy C means attained the fine results than the other previous algorithms. Anyway it takes more processing time for a single image. Hence, it can be overcome by the future proposed method. The performance value for the segmentation is given in table 1.

Table 1
Performance values for segmentation methods

<i>Performance Parameters</i>	<i>Statistical Region Merging</i>	<i>Novel Graph Technique</i>	<i>Region Growing</i>	<i>Hill Climbing</i>	<i>Semi Automated Segmentation</i>	<i>Fuzzy C-Means Clustering</i>
Sensitivity	76.48	79.68	84.52	85.14	87.14	88.14
Specificity	78.96	80.45	86.57	86.47	88.41	88.74
Accuracy	82.45	83.54	87.54	88.14	88.47	89.74

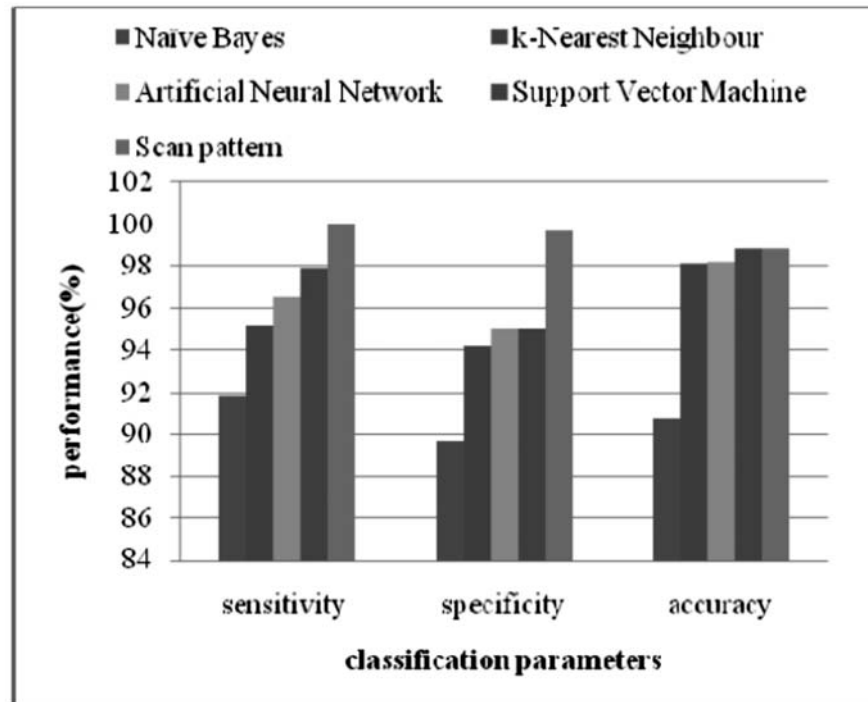


Figure 2: Graphical Representation of Performance Parameters of glaucoma classification methods

Fig 2 shows the graphical representation of glaucoma classification, it was analyzed by the parameters such as sensitivity, specificity and accuracy. The scan pattern achieved higher accuracy than the other classification method. Important issue concerned with scan pattern recognition is the estimation of the values of the parameters since they are not given in the practice. It can be overcome by the future work using new proposed technique. The performance values for classification methods are given in table 2.

Table 2

Performance values for classification methods

Performance Parameters	Naïve Bayes	K-Nearest Neighbour	Artificial Neural Network	Support Vector Machine	Scan Pattern
Sensitivity	91.79	95.12	96.6	97.9	100
Specificity	89.71	94.23	95	95	99.7
Accuracy	90.75	98.11	98.2	98.9	98.9

4. CONCLUSION

This survey paper depicts many works related to automated glaucoma detection. It is observed that a novel method is required to detect the Glaucoma. Many recent researches is being carried for detecting the Glaucoma using OCT and Fundus images, anyway progression of Glaucoma in patient remains to be researched. In future, we need to develop more accurate, robust as well as affordable automated algorithms for glaucoma detection, so that the benefits are passed to the affected by Glaucoma persons. Once glaucoma is correctly diagnosed then they can take proper medicine or undergo surgery in a timely manner to avoid total blindness. Then the image compression also plans to develop for efficient storage and communication purpose in medical field.

5. REFERENCES

1. Vaishali Kakade, Swati Madhe "Vessel Detection and Noise Suppression Methods of Optical Coherence Tomography (OCT) Images" International Journal of Modern Trends in Engineering and Research. e-ISSN No.:2349-9745, Date: 2-4 July, 2015.

2. Alexander Wong, Akshaya Mishra “General Bayesian estimation for speckle noise reduction in optical coherence tomography retinal imagery” <https://www.researchgate.net/publication/44852643>.
3. N. Padmasini, K.S. Abbirame, “Reduction of Speckle Noise in SDOCT Retinal Images by Fuzzification and Anisotropic Diffusion Filtering” *Biosciences Biotechnology Research Asia*, April 2015. Vol. 12(1), 671-676.
4. Chandrappa, Dharmanna Lamani “Segmentation of Retinal Nerve Fiber Layer in Optical Coherence Tomography (OCT) Images using Statistical Region Merging Technique for Glaucoma Screening” *International Journal of Computer Applications (0975 – 8887) Volume 128 – No.10, October 2015*.
5. “Cluster based Key Management Authentication in Wireless Bio Sensor Network “, *International Journal of pharma and bio sciences*, Impact Factor = 5.121
6. Bock, Rüdiger, Jörg Meier, Georg Michelson, László G. Nyúl, and Joachim Hornegger. “Classifying glaucoma with image-based features from fundus photographs.” In *Pattern Recognition*, pp. 355-364. Springer Berlin Heidelberg, 2007.
7. A Human Computer Interfacing Application “, *International Journal of pharma and bio sciences*, Impact Factor = 5.121
8. Ho, C. Y., Pai, T. W., Chang, H. T., & Chen, H. Y. (2011, June). An automatic fundus image analysis system for clinical diagnosis of glaucoma. In *Complex, Intelligent and Software Intensive Systems (CISIS), 2011 International Conference on* (pp. 559-564). IEEE.
9. Na, J. H., Sung, K. R., Baek, S., Kim, Y. J., Durbin, M. K., Lee, H. J., ... & Sohn, Y. H. (2012). Detection of Glaucoma Progression by Assessment of Segmented Macular Thickness Data Obtained Using Spectral Domain Optical Coherence Tomography Segmented Macular Layer Thinning in Glaucoma. *Investigative ophthalmology & visual science*, 53(7), 3817-3826.
10. Rajan, G.P. Ramesh “Automated Early Detection of Glaucoma in Wavelet Domain Using Optical Coherence Tomography Images” *Biosciences Biotechnology Research Asia*, December 2015. Vol. 12(3), 2821-2828.
11. K.A. Yogesh, and M. Sasikala, “Texture analysis of retinal layers in spectral domain OCT images,” *Int. J. Emerg. Technol. Adv. Eng.*, vol.2, pp. 296-300, 2012
12. Automatic detection of lung cancer nodules by employing intelligent fuzzy cmeans and support vector machine “, *Biomedical Research*
13. “Biologically Inspired Intelligent Robots Using Artificial Muscles” ,*International Journal of pharma and bio sciences*, Impact Factor = 5.121(Scopus Indexed).
14. Williams, D., Zheng, Y., Bao, F., & Elsheikh, A. (2015). Fast segmentation of anterior segment optical coherence tomography images using graph cut. *Eye and Vision*, 2(1), 1.
15. R. Nithya, N. Venkateswaran “Analysis of Segmentation Algorithms in Colour Fundus and OCT Images for Glaucoma Detection” *Indian Journal of Science and Technology*, Vol 8(24), IPL0342, September 2015.
16. Yazdanpanah, Azadeh, Ghassan Hamarneh, Benjamin R. Smith, and Marinko V. Sarunic. “Segmentation of intra-retinal layers from optical coherence tomography images using an active contour approach.” *Medical Imaging, IEEE Transactions on* 30, no. 2 (2011): 484-496.
17. Bizios, Dimitrios, Anders Heijl, Jesper Leth Hougaard, and Boel Bengtsson. “Machine learning classifiers for glaucoma diagnosis based on classification of retinal nerve fibre layer thickness parameters measured by Stratus OCT.” *Acta ophthalmologica* 88, no. 1 (2010): 44-52.
18. Soe Ni Ni, J. Tian “Anterior Chamber Angle Shape Analysis and Classification of Glaucoma in SS-OCT Images” *Journal of Ophthalmology* Volume 2014, Article ID 942367, Research article.
19. A. Rajan, Ramesh “Comparative Study of Glaucomatous Image Classification Using Optical Coherence Tomography” *G.PInt. J. Pharm. Sci. Rev. Res.*, 36(1), January – February 2016; Article No. 49, Pages: 277-280 ISSN 0976 – 044X.
20. N. Anantrasirichai, Alin Achim “SVM-Based Texture Classification in Optical Coherence Tomography” *International Journal of Pharmaceutical Sciences Review and Research*.
21. “Teleimersion” *Research Journal of Pharmaceutical, Biological and Chemical Sciences* on March – April 2016 issue.gh