

Detection of Cervical Cancer using the Image Classification Algorithms

M. Anousouya Devi*, S. Ravi** and J. Vaishnavi S. Punitha***

Abstract: Cervical cancer is the deadly cancer caused in women which affects the cervix region of the uterus. The cervical tissues are categorized into three types the Squamous Epithelium (SE), Columnar Epithelium (CE) and Aceto White (AW) Region. The AW region is used for diagnosing cervical cancer which is tested with acetic acid turns into white. A Biopsy of the tissue is taken where many computers assisted methods for screening cervical cancer (CC) which is discussed in this paper. In this paper, the several methods used for detecting cervical cancer is discussed which uses different classification techniques like support vector machine (SVM), fuzzy based techniques and texture classification to differentiate the normal, abnormal and cancerous cells.

Keywords: Cervical cancer, Pap smear test, Support vector Machine (SVM), Fuzzy based technique, Texture classification

1. INTRODUCTION

Cancer is a disease which is caused when cells in the human body grow old they die and new cells are replaced. The old cells when dies become damaged or they do not die and form a mass of tissue which grows into a tumor. Cervical cancer is the second occurring cancer in women of all age group. This cancer does not have any symptoms and cannot be detected at the early stage. The women from age group 15 and above are diagnosed with the Pap smear test which is a manual screening method used for the screening of cervical cancer. The cervical cancer is caused by the human Pamplova virus (HPV).

There are many gene types of HPV which leads to cancer and also does not lead to cancer. Cervix is the passageway in the uterus which connects the uterus and vagina. The cervix region is made up of three types of tissues columnar epithelium (CE), Squamous epithelium (SE) and the Aceto white (AW) region. There are two types of cervical cancer the squamous carcinoma and adenocarcinoma. The squamous carcinoma causes cancer cells when the cells present at the outer surface of the ectocervix change into cancer cells. The Adenocarcinoma lead to cancer when the glandular cells that produces the mucus in the ectocervix changes into cancer cells.

The manual screening of cervical cancer takes place in two ways. The very popular method is the Pap smear test where all women should intake this test once in a year. The doctor or the physician scrapes a small amount of cells from the uterus of the cervix region to find changes in the cervical cells before they change into cancer cells. The Pap smear test is very costly and only few experienced cytologists are available to conduct this test which leads to high false positive rates due to human error. The next manual screening method is the liquid based cytology (LCB) test used for detecting cervical cancer uses 5% acetic acid in the biopsy of the cervical tissues which changes the AW region into white color is a way of diagnosing cervical cancer.

* Research Scholar, Dept. of Computer Science, Pondicherry University, Pondicherry, Email: anousouyadevi@gmail.com

** Asst. Professor, Dept. of Computer Science, Pondicherry University, Pondicherry, Email: sravicite@gmail.com

*** Research Scholars, Dept. of Computer Science, Pondicherry University, Pondicherry, Email: roshugee@gmail.com, punitharesearch@gmail.com

In recent times, many manual screening methods have all been used in clinics for screening cervical cancer like HPV DNA test which is used to collect the cervical cells from the cervix region and test the cell DNA for HPV. Biopsy is another manual technique which is used for screening cervical cancer where a small amount of cervical tissue is taken for sample for screening cervical cancer. Coloposcopy is an instrument which is used to examine the cells of the cervix region.

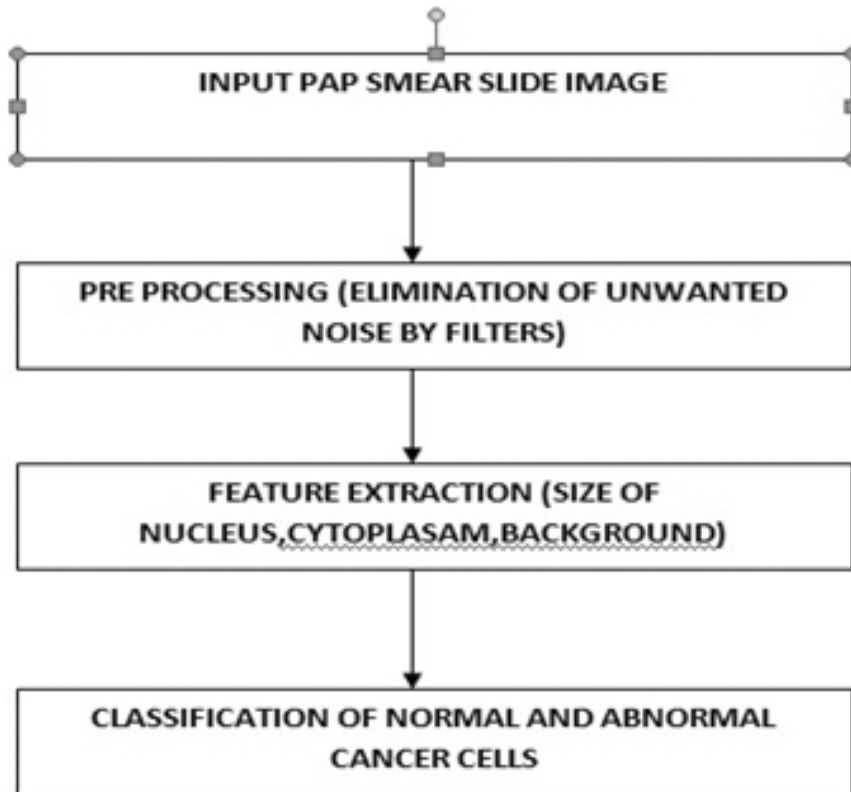


Figure 1: Steps in Digital Image processing

When cervical cancer is detected at the early stage with the pre-cancerous cells then a surgery can be done to remove the abnormal cells from the cervix. A cone biopsy test is used to remove the abnormal cancerous cells. A laser surgery procedure is used where a narrow beam of light which has high intensity is used for destroying cancer cells. When the cancer cells are in the severe stage then the radiotherapy and chemotherapy treatment are used for detecting the abnormal cells.

The manual screening method of cervical cancer with several methods suffers from accurate results and also time consuming. The computerized methods of classification are used for differentiating the normal and abnormal cells of the cervical cancer. The most common classification methods used are support vector machine (SVM), fuzzy based techniques and textural classification. The input image is fed where the preprocessing stage is performed by using filters to eliminate the unwanted noise from the image and enhance its quality by sharpening its edges and boundaries. The preprocessed image is used for feature extraction so as to extract the features of nucleus, cytoplasm and background. After the features are extracted, the nucleus and cytoplasm are segmented from the image. Finally the image is classified as normal, precancerous and abnormal cells.

2. CERVICAL CANCER DETECTION USING THE IMAGE CLASSIFICATION ALGORITHM

The classification of cervical cells is performed by many automatic methods by using an efficient classification algorithm. The nucleus cytoplasm features are extracted from the given input image and classified with an algorithm into normal, abnormal and precancerous cells.

2.1. Support Vector Machine (SVM)

The Cause of cervical cancer increases day by day. The challenging task in cervical cancer is the segmentation of nucleus and cytoplasm and identifying the cancer cells. A new radiating gradient vector flow (RGVF) algorithm is proposed by Kuan Li et al [1] which aim at the extraction of nucleus and cytoplasm in a single cervical smear cell. The cervical image is first extracted and pre-processing is carried out to roughly locate the nucleus and cytoplasm using k means algorithm. The new RGVF algorithm is used with a new edge map computational stack based refinement algorithm which neglects the false negative rates and locates the obscure boundaries effectively in nucleus and cytoplasm. The Herlev dataset with 917 images are taken as sample where the irregular boundaries of nucleus and cytoplasm for a single cervical cell are extracted.

The manual screening process in cervical cancer does not give accurate results. So a computer assisted system is proposed by Jian-Wei Zhang et al [2] for accurate segmentation of cervical cells. An adaptive algorithm based on gradient vector field (GVF) snake model is used to segment the nucleus and cytoplasm in the cervical smear cells. The image is first preprocessed and then the Otsu method is used to obtain the initial contours of the nucleus and set 16 parameters. The GVF snake model is used to make these contours into curve boundary and the nucleus is segmented. The quality of the image is measured in terms of its smoothness of the curve.

Rajesh Kumar et al [3] demonstrate an effective mass screening to avoid the quantity of false positive rates. The presence of artifacts which are in similar size and shape leads to misclassification of cytology images in the screening process. To avoid this misclassification the Support Vector Machines (SVM) is used to obtain a new pattern strategy for the detection of cervical cancer. SVM removes the artifacts from the epithelial cells. The image is acquitted by the E-smear software. The pre-processing is carried out by the median filter, the nuclear segmentation is performed by the edge based Laplacian of Gaussian. The classification is used with the SVM which is located at the middle of both support hyper planes.

Zhiyum Xue et al [4] classify the uterine cervical cancer with mosaic patterns, which is one of the visual symptoms which are used as an abnormality in the cervical tissues. The automatic detection of this vascular pattern in the cervical images is very challenging task. The mosaic regions are divided into two regions fine and coarse. The fine region has a network of thin calibres and the coarse region has a network of large calibres. A supervised learning approach is used to segment the mosaic vascular regions. Each segment is classified as mosaic tile which is combined as a binary map. The classification is done using Support Vector Machine with a Gaussian kernel function and validates the parameters.

Yinhai Wang et al [5] demonstrate an automated computer based system for the diagnosis of cervical intraepithelial Neoplasia (CIN) which is the cause of cervical cancer. The segmentation is divided into two parts: i) the squamous epithelium is segmented and again finely tuned into layers and the block based segmentation with robust texture features. The multi resolution method is developed to reduce the time of segmentation. The support vector machine (SVM) is used as the classifier for the normal and abnormal CIN. The classification is identified by the hierarchy of four binary classifications in different texture forms as perpendicular lines into normal, CIN1, CIN2 and CIN3. For each classifier the optimal set of features is used by systematic testing.

Fu Chen et al [6] demonstrate a semiautomatic screening for detecting cervical cancer. The detection is carried out with two ways, first with the rained set of data with cross validation SVM and the second part is the trained set of data with statistical analyser. The NCC detector and RW detector are used for detecting the boundaries and contours around the cell images. The SVM classifier is used to separate the multiple clusters with a set of hyper planes. The texture analysis is used with SVM for classification of normal and precancerous cells from the Pap smear slides. M. Orozco-Monteaquedo et al [7] propose a hybrid approach for extracting the nucleus and non-nucleus regions from Pap smear images in cervical cancer. It involves with two steps where the first phase uses a hierarchical partition on the unsupervised data and the second

step uses a support vector machine (SVM) to differentiate the normal and abnormal cells. The waterfall algorithm is used to partition the pixels in the Pap smear images as hierarchical unsupervised data where the boundaries are marked within the water level. The SVM region growing method classifies the region among the pixels as the nucleus and non-nucleus regions.

Carlos Arteta et al [8] propose a cell detection methodology using machine learning technique by using three steps. The first step is used to extract the cell structure regions and each region selected is evaluated by the dynamic programming to identify the overlapping regions. The ground truth configuration is generated by using a SVM which optimizes the inference from the training data set through structured learning.

Maykel Orozco-Montegudo et al [9] demonstrate an anomaly detection method for the segmentation of nucleus and cytoplasm in the uterine cervical cells. The region of interest (ROI) is used to collect the objects and sample tissues from the input image where the mean shift segmentation algorithm is used for segmenting the cervical cells. The anomalies are calculated by using a support vector machine (SVM) which evaluates the cytological information by giving a better performance of 71% than the other methods used.

Juan Valentín Lorenzo-Ginori et al [10] propose the best classification method for detecting the cervical cancer from the Pap smear slides. Four classifiers linear, KNN, Mahalanobis and SVM are used to classify the morphological features of cervical pap images which analyses the texture properties. The classifiers are experimented in the Helve Database which proves that the SVM-Mahalanobis gives better performance results than other classifiers.

Jiayong Zhang et al [11] propose a new feature screening algorithm for cervical cancer detection by using the decision boundary of support vector machine (SVM). The input image is first pre-processed from the background region bands. The feature extraction process is used detecting various image features like Wavelet analysis and Gabor filters. The feature screening is done by SVM where a sequential backward selection (SBS) method is used for screening procedure. The feature vector pixels are selected after SBS and the region detection is made on the selected pixel region. The proposed SVM method gives better performance in the cervical Pap smear test.

Chung-Chuan Cheng et al [12] propose a new automatic segmentation and classification method for detecting the boundaries of the Hep-2 cells and classified with their cell patterns. The anti-nuclear anti bodies ANA) image is used for the segmentation where the image is represented in RGB format and the original image is extracted from green dye. The cell contours are extracted from the general watershed algorithm. The support vector machine (SVM) classifier is used with radial basis function (RBF) to classify the labels and attributes in a non linear manner. Wei Wang Et Al [13] propose an ensemble classifier for segmenting the cervical tissue of the uterine. The multi-observer segmentation Evaluation system (MOSES) is a frame work that observers the multi users with two information the truth prior and ground prior for which a ground truth map is generated based on which the segmentation is performed. Multiple classifiers are trained in the ensemble framework where the support vector machine (SVM) combines with the trained data sets. The STAPLE algorithm is also combined which gives better performance and results on the trained data det.

Yang Liu Et Al [14] propose anew ensemble method classification with support vector machine (SVM) and binary particle swarm optimization (BPSO). The BPSO generate the initial population values with C1, C2 and C3 which are the feature subsets by using the Pop size. The fitness function is calculated for the generated features. The BPSO creates new optimal solutions by finding the velocity and dimension of each image pixel.

2.2. Fuzzy Based Techniques

The diagnosing of cancer cells in the cervical cancer is a tedious job as it has to be diagnosed in the pre-cancerous stage. The challenging task is to segment a single cell image into nucleus, cytoplasm and

background. Three different types of dataset are collected and extracted to differentiate the nucleus, cytoplasm and background regions. A patch based fuzz C means (FCM) clustering technique is used by Thanatip Chankong et al [15] for segmentation. A comparison is made with existing clustering techniques and watershed segmentation technique after the segmentation, a classifier is used to extract the related features from the input image. The single cell image is converted into a grayscale image and related to 4 class, 3 class and seven class problems for the LCH Pap smear dataset, ERUDIT pap smear test and Herlev Pap smear dataset respectively. The automatic cervical cell segmentation is more effective in LCH and Herlev Pap dataset, In ERUDIT data set in cannot view the image and divided it completely. Fabio Vaschetto et al [16] demonstrate that the cervix visual interpretation and examination plays an important role in the diagnosis and prevention of cervical cancer. This method when done with the intervention of humans suffers from errors so to create an error free system an automated system THREECOND is proposed which not only segments the nucleus automatically but also classifies the normal and abnormal cells. THREECOND integrates the color information, knowledge from pathologist and fuzzy systems. The color representation consists only of three colors pink, blue and transparent cell nucleus with the model with HSI. The segmentation of nucleus is performed by marking the irregular boundaries. The classification is done by a set of unsupervised fuzzy system which after segmentation classifies the normal and abnormal cells with fuzzy rules.

Marina E. Plissiti et al [17] propose a classification method for cervical cells only with the nucleus features and ignoring the cytoplasm features. It combines two classifiers the spectral clustering and Fuzzy C-means for classifying the normal and abnormal cells. Two unsupervised data sets are used to evaluate the performance of these two classifiers where the features like area, brightness, background and perimeter are extracted with the nuclei features for normal and abnormal criteria.

Kwang-Baek Kim et al [18] demonstrate a new method for detecting the nucleus and cytoplasm from the cervix uterine region. The input image extracted from the uterine is converted into greyscale image. The unwanted noise is eliminated in the image by using a compressor and grey morphological operator. The classification and recognition of nucleus is performed by the combination of fuzzy logic and ART learning model. The fuzzy ART algorithm classifies the nucleus into normal, abnormal and cancerous cell. The proposed method is efficient which uses the HSI model with the TBS data sets.

Kwang-Baek Kim et al [19] propose a new segmentation method for the uterine cervical image by using a fuzzy C means algorithm with HSI model. The input image is first pre-processed by removing the unwanted noise from the image. The Fuzzy C means algorithm divides the image into clusters by the Euclidian distance. It uses a classification matrix based on the threshold value for the recognition of normal and abnormal nucleus.

2.3. Textural Classification

The nucleus and cytoplasm texture analysis is very important for the classification of cervical cancer histology. The Gabor filter banks are used by Rahmadwati G. Naghdy et al [20] for the texture analysis where the image is segmented into five possible regions. The features are segmented into background, normal, abnormal, basal and stoma cells. Each pixel and its neighboring pixel are comprised with a feature vector which is attached to each filter. The input is given as the biopsy image of the cervix which contains the epithelium layer. The segmentation is made to divide the input image as Gabor function which is a complex sinusoid modulated with a Gaussian function. Twenty four distinctive Gabor filters are used to generate a feature vector for each pixel. A hybrid k-means clustering algorithm is used for segmenting the cells and differentiates it into normal and pre cancer cells.

Krishnaveni et al [21] presents a method to classify the textural features of the nucleus and cytoplasm segmentation. The sense of touch with the texture can yield more information than visual and other senses.

The segmentation of nucleus and cytoplasm provides many textural features to be analyzed for the segmentation. The input image is obtained and represented in RGB model. The pre-processing process converts the color image into gray scale image and the removal of noise is filtered. There are four textural features to be extracted for each stage of cancer. The mean, standard deviation, skew and kurtosis are used to analyze the obtained textural features.

Yeshwanth Srinivasan et al [22] explore the classification of the cervical lesions with filters and texture models. The texture based models fails to classify the mosaic patterns and punctuations. The proposed approach with the filter banks targets to segment the punctuations with the Gaussian template and matches with the filtering. The colposcopic image is converted into gray scale image where 38 filters are involved for each image. This novel approach eliminates the punctuations and classifies the textural patterns in the digital images of the cervical tissues.

Bhakthi Tulpule et al [23] demonstrate automated segmentation method with mosaic patterns classified by its textural analysis as normal and abnormal cells. The purpose of segmentation is to locate the biopsy of the tissues for diagnosis. The Aceto White region (AW) is the major tissue that indicates the visual interpretation of cervical cancer lies in the acetic acid test. This layer is first segmented by using a non-convex optimization approach. The abnormal feature present in the AW is segmented into mosaic patterns. The pattern is classified into its texture analysis by using a fuzzy c-means algorithm to classify the normal and abnormal cells in the cervix. The Fuzzy C-means calculates the percentage of edges observed in a region which determines the rate of abnormality at each pixel.

2.4. Adaboost Classifier

Tao Xu Et Al [24] propose an adjustable adaboost classifier for CIN classification of the cervical cancer. The image is split into rectangular sub regions where each sub region is increased with a boosting learning. The pyramid feature extraction process is used to generate a gradient map for each sub region pyramid where the pyramid histogram of oriented gradients (PHOG). A multi feature descriptor is used to concatenate the three different types of features extracted by using a stump which identifies the weak classifier. The optimal threshold for each feature stump that minimizes the error is a weak classifier

2.5. Cell Detect Technique

The detecting of cervical cancer is diagnosed with a newly invented technique with stained targeted cytoplasm called cell detect staining. The normal cytoplasm cells are green and dysplastic or neo plastic cells are purple/red. The collected sample Pap smear image slides are immersed in 95% ethanol for duration of 30 min to view an enlarged image nucleus the image is immersed in formaldehyde and paraffin. The irregularity of nuclear membrane and the ratio of cytoplasm can be identified by the staining method easily. The color of the segments helps in easy detection of the boundary regions 600 human cervical specimens are collected from Nantong Tumor hospital and analyzed with cell detect staining test [24].

2.6. Hierarchical Clustering

The cervical cancer diagnosis among the pre-cancerous and normal cells is very difficult because there are 10,000-20,000 cell images in a Pap smear slide. The visual abnormality can be seen only in a small range of cells. The remaining cells need to be digitized. The problem in digitized images is poor standardization, larger file size and slow acquisition speeds. The smear cells are unevenly distributed and there thickness cannot be predicted and the image file size is larger. In this paper, an extended depth of field algorithm (EDF) is proposed by Yilum Fan et al [25] to analysis the clump thickness of the Pap smear slides. It also determines the optimal number of focal planes required to analyze the thickness by using a focal map. The each of view (EOV) image is converted into a composite image by using EDF

algorithm and the central focal plane is located and the smear slide thickness is measured.

2.6 Expectation–Maximization (EM) Algorithm

The reliable ground truth (GT) is collected from large medical repository of cervigrams from the national cancer institute (NCI) where 939 cervigrams into regions using STAPLE (Simultaneous Truth and Performance Level Estimation) algorithm. The proposed system automatically generates multi expert ground truth segmentation by using a ground truth map. The STAPLE algorithm is a well-known method which is used by Shiri Gorden et al [26] to generate the segmentation process of ground truth for multiple observations. The input is given as a binary image segmentation where the object pixels are marked as one and background pixels are marked as zero. The performance level is analyzed by using Expectation–Maximization (EM) algorithm to estimate the parameters of the performance level.

2.7 Loop Medicated Isothermal Amplification Method (LAMP)

The cervical carcinoma is caused by the human papilloma virus (HPV) infections in the epithelial cells of the cervix region in the uterus. There are many morphological, cytological and DNA based a technique which helps in the detection of high risk HPV. The expression level of the host cell bio markers helps to identify the cornucopia with the particular viral genotype. There are 120 different genotypes of HPV. The diagnostic method must be with high specificity and sensitivity values. The system proposed by Memorna Ramzan et al [27] is a DNA based technique called Loop medicated isothermal amplification method (LAMP) which collects the targeted tissue samples in the temperature range 63-65c and immersed in magnesium pyrophosphate the color changes in the tissue cells are used for screening.

2.7. SISCOLO

The Cervical Cancer is second most deadly cancer caused in women. The SISCOLO Brazilian cervical cancer information system that collects the details of women in a format of two tables i.e. histology and cytology. The attributes used inside the tables are name, date of birth, address etc. The essential detail is used to find the hereditary disease caused in them. Once all these data are collected in the table to combine this computerized information a file has been named record linkage. The data can also be collected from cervix pathological examination and Pap smear test. The ReLink software was used to split the names into last name, first name and middle name. The linking procedure was used by Freire et al [28] to combine the common names in both the tables used.

2.8. Bio Markers

The cervical cancer transition in cervical cells is caused by the oncoprotein cancerous inhibitor (CIP2A) which interacts with the protein phosphate and stabilize C-Myc. The high expression levels of CIP2a results in poor clinical outcomes in multiple cancers. The system proposed by Yi Wu et al [29] provides a correlation between the proteins expression and expression levels of two cores epithelial to mesenchymal (EMT). The bio markers use this CIP2A expression levels for the transition of normal cells to cancer cells. The protein synthesizer P90 regression is also a cause of cervical cancer transition [29].

2.9. Luciferase Assay Method

There is multiple MiR involved in the radio resistance of cervical cancer. There are only limited studies that regulate mechanism of Mir Nas. The HR-HPV positive diagnosis cervical cancer but the detailed regulative network of MiR-21 is still not clear in the radio resistance therapy. The Mir-21 over expression is associated with higher level of HR-HPV positive cancer cells. This infection leads to a series of deregulated molecular process. The proposed method by Shikai Lui et al [30] demonstrates a dual luciferase assay method where a verified binding site between MiR-21 and large tumour suppression (LAT) is connected and analysed detect the HR-HPV positive cells.

2.10. Tumour Detection

The magnetic resonance images (MRI) needs to be assessed with reliability where the growth of tumors extension by comparing the MRI Image samples. The tumor growth in the uterus cervical region needs to be predicated in the MRI images and detected in the early operative stage hysterectomy specimen. Peter Deboer et al [32] proposed a method that detects the tumour growth in the uterus around the cervix region and detects it as a cancer or precancerous cell which helps in diagnosis of cervical cancer.

3. DISCUSSION

The survival rate of cervical cancer is increasing day by day. The women must undergo the cervical cancer screening once in two years. The main drawback of cervical cancer is it has no symptoms for detecting it at the earlier stage hence mostly it is detected at the post cancer stages of cervical cancer. A biopsy of the cervical tissue is sampled for analysis of cervical cancer with the AW region color changes. There are many computerized methods available for detecting cervical cancer with good accurate results. The present techniques still lacks in accurate results and enhancement to be used as clinical tool. The computerized techniques will be enhanced in future to provide better accurate results and decrease the false positive rates. There regulates the growth of cervical cells and prevents the abnormal growth.

The computerized techniques are used for the classification of cervical cancer for easy diagnosis and accurate classification results. The detection of cervical cancer suffers from high false positive rates when diagnosed manually. The manual screening of cervical cancer is inefficient because of the human error in segmenting and classifying the cells. The cell structure is very complex because of the irregular boundaries and overlapping regions. The identification of this process is time consuming when performed manually by the cytopathologist. The classification of cervical cancer is analyzed with the nucleus and cytoplasm of the cell structure. The nucleus is present at the center of the cell structure which is surrounded by the cytoplasm. The irregular and overlapping regions of nucleus and cytoplasm must be identified by segmentation methods. After the segmentation process, the cells are classified as normal and abnormal cells. All abnormal cells are not cancerous cells. The classification process has to be done as normal, abnormal and precancerous cells with the features of nucleus and cytoplasm. In normal cell, there is only presence of a single nuclei and the nucleus and cytoplasm ratio is high. In abnormal cell, there is multiplication of the nucleus structure and the nucleus and cytoplasm ratio is low.

The computerized techniques makes it easier for detecting the cervical cancer with various classification techniques like support vector machine, fuzzy based techniques, classification by the textural analysis of the cell structure and other techniques are used in the detection of cervical cancer. The analysis of the classification methods are presented in a survey table where the Table 1 discusses the performance of the Support vector machine techniques Table 2 shows the description about the fuzzy techniques used, Table 3 presents the analysis on the results obtained by the techniques used with textural classification. The index of the table is expanded as given below

- The first name of the author is used as the reference of the paper
- The methods which are used along with classification technique is mentioned
- The features which are extracted for classification of the normal and abnormal cells are mentioned
- The merits and demerits of the technique used is discussed
- The dataset images that are used for the experimental set up is discussed
- The accuracy and metrics of the technique is represented in percentage and false positive values

The support vector machine (SVM) is used as a classifier in many bio medical images. Table 1 presents a detailed description of the various SVM techniques used for detecting cervical cancer. This technique

produces the best accurate classification results between the normal and abnormal cells. The radial basis function (RBF) is used along with the support vector machine for classification of the cervical cells gives a good performance [4] [12] where the segmentation of the cells are performed accurately but the system suffers with a unique pattern for each cell classification which leads to confusion in detection or retrieval. The SVM with machine learning techniques and region growing algorithm obtains good classification accuracy results [7] [10] which is time consuming in separating the overlapping regions of the cells structure. The SVM is used with a nucleus cytoplasm (NCC) detector [6] which is used for the detection of normal and abnormal cervical cells where the image is represented in gray levels with good accuracy results. For implementing it in clinical usage more statistical tools are required. The SVM methods extracts the texture features with good performance results [9] [10] [11]. The SVM classification of cervical cancer uses the standard deviation, mean and median [13][14] as a metrics which classifies every individual cervical cell. The storage is increased for all cell structure to be stored. The fuzzy technique with the clustering classification [15] produces better classification results where the input image is divided into pixels by calculating the neighbor pixel values the classification of normal and abnormal cells is performed. Table 2 summarizes the pros and cons of using the fuzzy classification. The Fuzzy classification uses three condition rules [16] for classification of normal and abnormal cells which uses only limited features for extraction and does not detect the transparent cells for classification results.

The textural classification of cervical cells analysis the texture of the nucleus and cytoplasm with the darker shades are the nucleus regions. The lighter region is the cytoplasm regions in the cell structure. Table 3 represents the accuracy of the various texture classification methods for differentiating the normal and abnormal cervical cells. The Gabor filters [20] are used to extract the textural properties of the cervical cells. The specificity value of the cells are obtained only for the larger image size values. The textural classification is used for detecting the pre and post cancerous [21] stages in the cervical cells. The textural features are extracted from the cell images by using the morph metric and isometric features [22][23].

There are other classification methods for detecting cervical cancer using the protein synthesizer methods. Table 4 represents the description about other classification techniques. The proteins extracted from the plants regulate the growth of cells which can be extracted from cells with the normal and abnormal values.

The aadaboost technique is used with fuzzy C means for analyzing [24] the color perception changes in the Aceto White (AW) region. There are three linking procedures [29] available for obtaining the protein values in databases. A biomarker is used for identifying or to combine the protein synthesizers [30] in cervical cells but the degree of expression is very high for the protein levels. The dual Lucifer assay method is used for diagnosing the HPV positive for the cervical cells but it does not takes the entire growth of cervix region. The tumor growth in the cervix also leads to cervical cancer. The detection of tumor is scanned from an MRI image [32] which needs to analyze for normal and abnormal cells. All tumor growth does not lead to cancer. The precancerous cell must be detected and treated immediately before it changes

Table 1
Survey table of support vector Machine

<i>Author's Name</i>	<i>Method</i>	<i>FeaturesExtracted</i>	<i>Advantage</i>	<i>disadvantage</i>	<i>Dataset</i>	<i>Accuracy/Metrics</i>
Kuan Li et Al,[1]	Radiating gradient vector flow (RGVF)	Contours of nucleus Cytoplasm and background	Identifies obscure boundaries of nucleus and cytoplasm	initial contour is close to the object must be placed nearby	Herlev dataset, 917 images	0.95457+-0.0439
ZHANG, J.-W et Al[2]	Gradient Vector Field(GVF)Model	Extracts the initial active contours	Smoothness is used as a parameter for	segmentation of nuclei is depend-	411 typical images Guangzhou	95.134%

(contd...)

(Table 1 *contd...*)

<i>Author's Name</i>	<i>Method</i>	<i>FeaturesExtracted</i>	<i>Advantage</i>	<i>disadvantage</i>	<i>Dataset</i>	<i>Accuracy/Metrics</i>
Rajesh Kumar R Et Al[3]	Support Vector Machine with Sequential Minimal Optimization (SMO) method	morphological features Nuclei Area and Eccentricity and Fourier Coefficients	Elimination of artifacts from cytology images helps for better classification	extracting the right contour for effective performance ent on certain parameters more time for classification of normal and abnormal cells	University of Traditional Chinese Medicine Bethesda System	True Classification 85.19% 88.1% False Classification 11.9% 14.81
Zhiyun Xue Et Al [4]	Gaussian RBF kernel function	Texture features	automatically extracts the mosaic vascular features easily	limited number of features are being extracted	39 cervigrams	674 SVM positive training examples and 1789 SVM negative training examples
Wang, Y Et Al[5]	radial basis function (RBF)	nucleus boundary cytoplasm boundary background	used as a clinical tool for diagnosing CIN	very time consuming	20 H&E stained cervical histological slides	–
Chen, Y Et Al[6]	SVM with Nucleus cytoplasm detector	–	Eliminates the gray level zones in the cervical tissue	More statistical tools are needed for its clinical usage	–	97.16%
M. Orozco-Monteagudo Et Al [7]	SVM with region growing	nucleus and non-nucleus regions	best hierarchy level is selected for segmentation of pap smear images	segmentation of separating cells does not give better results	–	97.143
Carlos Arteta et Al [8]	SVM with machine learning technique	Overlapping regions of nucleus and cytoplasm	easy to change the cell size and image intensities	does not give accurate results for cell clumping of overlapping cells	ICPR 2010 Histopathology Images	precision, recall and F1-score 86.99 90.03 88.48
Maykel Orozco-Monteagudo Et Al [9]	Support vector machine	area factor, relative area compactness	regions are extracted without wasting the small regions and noise	abnormal cells are not frequently detected from the overlapping regions	40 images taken in the Gynaecological-Obstetrical Hospital of Santa Clara	Recall Precision F-measure
Juan Valentín Lorenzo-Ginori Et Al [10]	Support vector machine	Heraldic features	more accurate classification results for predicting the negative values	texture features of the nucleus alone is extracted which does not give accurate results	Herlevdatabase which contains 917 annotated images	–
Jiayong Zhang et al [11]	Support vector machine	pixel intensity	improve the pixel level classification	Large pap smear slides do not give better results	40 images of pap smear slides	–
Chung-Chuan Cheng et al [12]	Radial basis function(RBF)	Tamura features, coarseness, contrast, and directionality	easy process for cell segmentation with patterns	segmentation method consists images only with unique patterns	3830 cells extracted from 196 images are classified into 6 different patterns	96.90%
Wei Wang Et Al [13]	MOSES	Foreground background and textural features	performs classification for every individual cells	high computing time and increased storage	939 cervigram images	Mean and standard deviation
Yang Liu Et Al [14]	SVM	–	chooses the nearest neighbour in the pixel and classifies	efficiency of the cost function calculation is low	939 cervigram images from the NCI/NLM	Bhattacharyya distance based metric

Table 2
Survey table on Fuzzy techniques

<i>Author's Name</i>	<i>Method</i>	<i>FeaturesExtracted</i>	<i>Advantage</i>	<i>disadvantage</i>	<i>Dataset</i>	<i>Accuracy</i>
Thanatip Chankong et al [15]	Fuzzy C means Clustering	Nucleus and entire cell m morphology during the cell division	segments a single cell image into nucleus cytoplasm and background	difficult to analyse at the coarsens of the texture analysis of nucleus	ERUDIT dataset LCH dataset Herlev Dataset	95.00% and 97.00% 93.78% and 99.27%
Fabio Vaschetto et al[16]	THRECOND	–	nucleus in Pap smear slides is detected with easy colour detections	transparent cells present in the image are not detected	15 cervicismsear colour collected at the Hospital de Sant Pau de Barcelona,	–
Marina E. Plissiti et al[17]	Fuzzy C-means	twenty features concerning intensity a shape characteristics	reduction of non linear discrimination increases the accuracy	extracted features of cytoplasm are not used for classification	–	–
Kwang-Baek Kim et al [18]	fuzzy ART algorithm	Morphometric features, densitometric features, colorimetric features textural features	efficient method for classifying the abnormal and cancer cells	misclassification sometimes with the open nucleus classifying the normal cell into abnormal cell	20 samples of cervix uteri Pusan university hospital	extraction rate is 89.8%
Kwang-Baek Kim[19]	fuzzy C means algorithm	13 morphometric features, 8 densitometricfeatures, 18 colorimetric features, textural feature	detection of nucleus is identified with simple steps	segmentation of nucleus is not considered with the whole image	20 samples of Pusan university hospital	

Table 3
Survey table on texture classifications

<i>Author's Name</i>	<i>Method</i>	<i>FeaturesExtracted</i>	<i>Advantage</i>	<i>disadvantage</i>	<i>Dataset</i>	<i>Accuracy</i>
Rahmadwati G. Naghdy Et Al[20]	Gabor filter banks	Textural features	texture analysis is used to classify the normal, abnormal and cancer cells easily	greater size of the image only gives better specificity values	biopsy images anatomy laboratory of Saiful Anwar hospital	–
Krishnaveni et al [21]	Textural classification	Mean, standard deviation, skness and kurotosis textural features of cells	detect the different stages of cancer with the textural features	More textural features can be embedded for accurate results	Cyto images	–
Yeshwanth Srinivasan Et Al [22]	Gaussian template	Texture and mosaic	segments the meaningful punctuations in the cervix images easily	no accurate measurement of the punctuation sizes	cervicographic and colposcopic images	–
Bhakthi Tulpule et al[23]	fuzzy c-means algorithm	T textural and morphological features	automatically locate the abnormal region in the cervix	accuracy of the performance is not stabilized	Colposcopic and Cervicographic images	–

into cancer cells. The stages of cancer are analyzed with growth in tumor at different stages. It is very difficult to regulate the growth of cancer cells at the final stage. There are many therapies used for stimulating the growth of cancer cells and increase the survival rate. In future, there are many more promising computerized techniques used for detecting cervical cancer.

Table 4
Other Technique

<i>Author's Name</i>	<i>Method</i>	<i>FeaturesExtracted</i>	<i>Advantage</i>	<i>disadvantage</i>	<i>Dataset</i>	<i>Accuracy</i>
Tao Xu Et Al[24]	adaboost classifier	colour features of AW is extracted	feature map is constructed for all sub regions to locate them easily	boosted decision trees are dependent on the loss function values	database collected by NCI	86.39% sensitivity 74.21% specificity
Song he et Al[25]	cell detect staining	Nuclear size, cytoplasam size and nucleus and cytoplasm ratio	used to differentiate the normal and abnormal cells easily	magnificent rate is low	600 human cervical specimens Nantong Tumor Hospital	sensitivity and specificity 94.34% and 88.73%,
Yilum Fan et al [26]	extended depth of field algorithm (EDF)	Nucleus cytoplasm and thickness	detect the thickness of the pap smear slides	selection of focal plane has to done for each slide	FOV images	focus metric 95%
Shiri Gorden et al [27]	STAPLE	AW region	segmentation of the cervix region is transparent and easy to segment	aceto white segmentation is more complex	Cervigram	–
Memorna Ramzan et al [28]	LAMP	Cell features of pap slides	tissues infected by HPV virus is easily detected	detection of viral DNA is difficult	–	–
Freire et al[29]	linking procedure	–	three linking procedures used analysis and measures the values in the table easily	linkage values are not consecutive which leads confusion	National Cervical Cancer Information System–SISCOLO	Sensitivity specificity and precision 90% and 100%
Yi Wu et al[30]	bio markers	–	identifies the relation between the protein synthesiser used for cervical cancer	high expression levels of protein synthesiser leads to multiple cancers in clinical test	–	–
Shikai Lui et al [31]	dual luciferase assay method	–	helps to clearly diagnosis the HPV positive in the cell structure	does not accurately regulate the growth of cells in the cervix	–	–
Peter Deboer et al [32]	Tumour Detection	–	tumour growth in the cervix region is easily detected with the MRI images	Tumor classification can be classified with the post cancer stages	–	Mean median and standard deviation

4. CONCLUSION

Cervical cancer is screened manually by using the Pap smear test and LCB test which does not give accurate classification results in classifying the normal and abnormal cervical cells in the cervix region of the uterus. The manually screened method suffers from high false rate due to human error and also cost effective to be carried out by the experienced cytologist. In this paper, a study and analysis is done for the automatic detection of cervical cancer using various classification methods. The computerized techniques are performed to produce accurate results and to make effective classification of normal and abnormal cells. In future, a multi observer technique with RGB color space model will be used for detecting the color images of cervical tissues. The AW region which posses a white color change with acetic acid test can be modeled for the detecting of cervical cancer

References

- [1] “Cytoplasm and nucleus segmentation in cervical smear images using radiating GVF snake”, Kuan Li et Al, 2011.
- [2] ZHANG, J.W., ZHANG, S.S., YANG, G.H., HUANG, D.C., ZHU, L., & GAO, D.F. (2013). Adaptive Segmentation of Cervical Smear Image Based on GVF Snake Model. Proceedings of the 2013 International Conference on Machine Learning and Cybernetics, 14–17.

- [3] Kumar, R. R., Kumar, V. A., Kumar, P. N. S., Sudhamony, S., & Ravindrakumar, R. (2011). Detection and removal of artifacts in cervical Cytology images using Support Vector Machine. 2011 IEEE International Symposium on IT in Medicine and Education, 1, 717–721. <http://doi.org/10.1109/ITiME.2011.6130760>
- [4] Xue, Z., Long, L. R., Antani, S., & Thoma, G. R. (2010). Automatic extraction of mosaic patterns in uterine cervix images. Proceedings-IEEE Symposium on Computer-Based Medical Systems, 273–278. <http://doi.org/10.1109/CBMS.2010.6042655>
- [5] Wang, Y., Crookes, D., Eldin, O. S., Wang, S., Hamilton, P., Diamond, J. (2009). Assisted Diagnosis of Cervical Intraepithelial Neoplasia (CIN). IEEE Journal of Selected Topics in Signal Processing, 3(1), 112–121. <http://doi.org/10.1109/JSTSP.2008.2011157>
- [6] Chen, Y.F., Huang, P.C., Lin, K.C., Lin, H.H., Wang, L.E., Cheng, C.C., ... Chiang, J. Y. (2014). Semi-automatic segmentation and classification of Pap smear cells. IEEE Journal of Biomedical and Health Informatics, 18(1), 94–108. <http://doi.org/10.1109/JBHI.2013.2250984>
- [7] Sahli, H., & Mihai, C. (2011). A Hybrid Approach for Pap-Smear Cell Nucleus, 174–183.
- [8] Arteta, C., Lempitsky, V., Noble, J. A., & Zisserman, A. (2012). Learning to Detect Cells Using Non-overlapping Extremal Regions, (Figure 1), 348–356.
- [9] Orozco-monteaugudo, M., Taboada-crispi, A., & Sahli, H. (2013). in Pap-Smear Images, 17–24
- [10] Lorenzo-ginori, J. V., & Curbelo-jardines, W. (2013). Cervical Cell Classification Using Features Related to Morphometry and Texture of Nuclei, 222–229.
- [11] Zhang, J., & Liu, Y. (2004). Cervical Cancer Detection Using SVM Based, (2), 873–880
- [12] Cheng, C.C., Hsieh, T.Y., Taur, J.S., & Chen, Y.F. (2013). an automatic segmentation and classification framework for anti-nuclear antibody images. Biomedical Engineering Online, 12 Suppl 1(Suppl 1), S5. <http://doi.org/10.1186/1475-925X-12-S1-S5>
- [13] Wang, W., Zhu, Y., Huang, X., Lopresti, D., Xue, Z., Long, R., ... Thoma, G. (2009). A CLASSIFIER ENSEMBLE BASED ON PERFORMANCE LEVEL ESTIMATION Department of Computer Science and Engineering, Lehigh University, Bethlehem, PA 18015 Communications Engineering Branch, National Library of Medicine, MD 20894. Performance Evaluation, 342–345.
- [14] Liu, Y., Zhou, J., & Chen, Y. (2008). Ensemble Classification for Cancer Data. BioMedical Engineering and Informatics, 2008. BMEI 2008. International Conference on, 1, 269–273. <http://doi.org/10.1109/BMEI.2008.161>
- [15] Automatic Cervical cell segmentation and classification in Pap Smears”, Thanatip Chankong Et Al, 2013.
- [16] Vaschetto, F., Dipartimento, D., Montseny, E., & Lerma, E. (2009). THREECOND/ : An Automated and Unsupervised Three Colour Fuzzy-Based Algorithm for Detecting Nuclei in Cervical Pap Smear Images. <http://doi.org/10.1109/ISDA.2009.212>.
- [17] Plissiti, M. E., & Nikou, C. (2013). Cervical Cell Classification Based Exclusively on Nucleus Features, 483–490.
- [18] Kim, K., Kim, S., & Sim, K. (2006). Nucleus Classification and Recognition of Uterine Cervical Pap-Smears Using Fuzzy ART Algorithm, 560–567.
- [19] Kim, K.B., Kim, S., & Kim, G.H. (2007). Nucleus classification and recognition of uterine cervical pap-smears using FCM clustering algorithm. Adaptive and Natural Computing Algorithms, Pt 2, 4432, 290–299.
- [20] Rahmadwati, Naghdy, G., Ros, M., Todd, C., & Norahmawati, E. (2011). Cervical Cancer Classification Using Gabor Filters. 2011 IEEE First International Conference on Healthcare Informatics, Imaging and Systems Biology, 48–52. <http://doi.org/10.1109/HISB.2011.15>
- [21] Krishnaveni, K., Allwin, S., & Kenny, S. P. K. (2010). Analysis for Textural Features in Nuclei of Cervical Cyto Images
- [22] Srinivasan, Y., Nutter, B., Mitra, S., Phillips, B., & Sinzinger, E. (2006). Classification of Cervix Lesions Using Filter Bank-Based Texture Models.
- [23] Tulpule, B., Yang, S. Y. S., Srinivasan, Y., Mitra, S., & Nutter, B. (2005). Segmentation and Classification of Cervix Lesions by Pattern and Texture Analysis. The 14th IEEE International Conference on Fuzzy Systems, 2005. FUZZ '05., 173–176. <http://doi.org/10.1109/FUZZY.2005.1452388>
- [24] Xu, T., Kim, E., & Huang, X. (2015). ADJUSTABLE ADABOOST CLASSIFIER AND PYRAMID FEATURES FOR IMAGE-BASED CERVICAL CANCER DIAGNOSIS Computer Science and Engineering Department, Lehigh University, Bethlehem, PA, USA/ ;, 281–285.[16] Automatic Cervical cell segmentation and classification in Pap Smears”, Thanatip Chankong Et Al,2013
- [25] Application of the cell detect and staining technique in diagnosis of human cervical cancer, Song he et Al 2013
- [26] A method for quantitative analysis of clump thickness in cervical cytology slides”, Yilum Fan, 2016

- [27] Evaluation of uterine cervix segmentation using ground truth from multiple experts, Shiri Gorden Et Al, 2008.
- [28] A Cornucopia of screening and diagnostic techniques for human papilloma virus associated cervical carcinomas, Memorna Ramzan Et Al, 2015
- [29] A record linkage process of a Cervical cancer screening database”, Sergio Miranda Freire Et Al, 2012
- [30] CIP2A cooperates with H-Ras to promote epithelial mesenchymal transition in cervical cancer progression, yi Wu Et Al, 2014
- [31] MiR-21 modulates resistance of HR-HPV positive cervical cancer cells to radiation through targeting LATS1 Shikai Lui Et Al, 2015.
- [32] Craniocaudal tumor extension in uterine cervical cancer on MRI compared to histopathology, Peter Deboer Et Al, 2015.